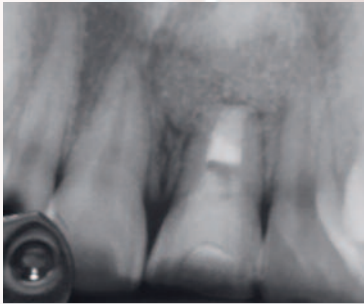


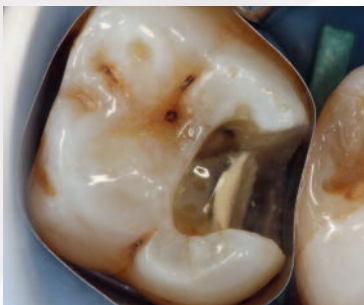# Septodont Case Studies Collection

No. 14 - October 2016

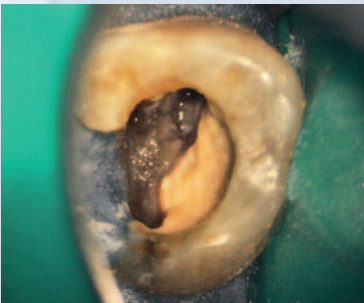
**BIODENTINE™**  
Retrofilling in apicectomy  
Dr. A. Segovia Ramirez



**BIODENTINE™**  
Deep caries treatment  
Dr. M. Federlin



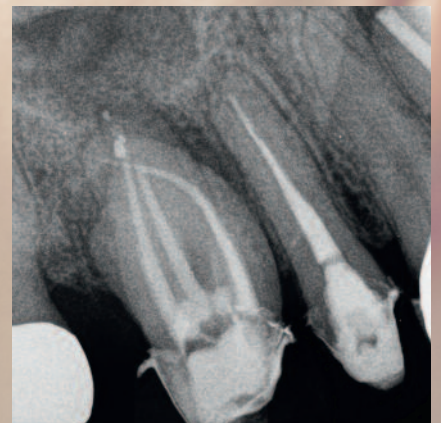**BIODENTINE™**  
Perforation repair treatment  
Dr. J. Abarca Reveco



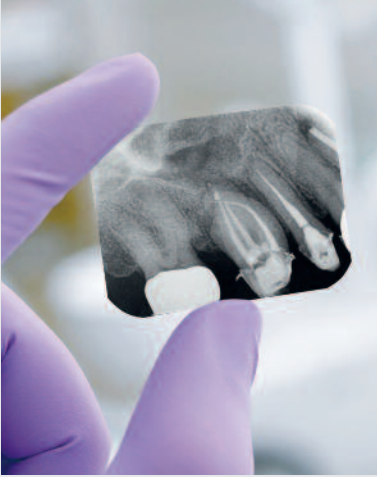
## BioRoot™ RCS

Upper molar  
with  
periradicular  
perforation

Dr. E. Ambu



# Editorial



Since its foundation Septodont has developed, manufactured and distributed a wide range of high quality products for dental professionals.

Septodont recently innovated in the field of gingival preparation, composites and dentine care with the introduction of Racegel, the N'Durance® line and Biodentine™, which are appreciated by clinicians around the globe.

Septodont created the “*Septodont Case Studies Collection*” - a series of case reports - in 2012 to share with you their experience and the benefits of using these innovations in daily practice.

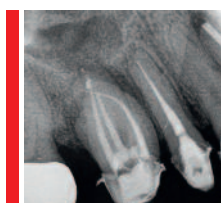Over the past 4 years, authors from more than 15 countries have generously contributed to the success of our magazine that is now distributed on the 5 continents.

Each new issue of the Case Studies Collection is the opportunity to discover new clinical challenges and their treatment solutions.

This 14<sup>th</sup> issue features three Biodentine™ cases and a new case report on the most recent Septodont Innovation : BioRoot™ RCS.

- BioRoot™ RCS is the new paradigm for endodontic obturations. Its outstanding sealing properties combined with antimicrobial and bioactive properties allow to get a high seal of the endodontium without having to use complex warm gutta techniques.
- Biodentine™, the first biocompatible and bioactive dentin replacement material. Biodentine™ uniqueness not only lies in its innovative bioactive and “pulp-protective” chemistry, but also in its universal application, both in the crown and in the root.

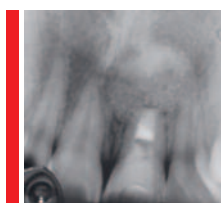
# Content



## Endodontic retreatment of an upper molar with periradicular perforation and lesion

Dr. Emanuele Ambu

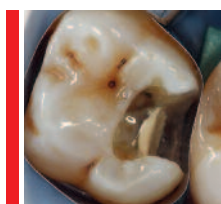04



## Retrofilling with Biodentine™ in apicectomy

Dr. Alberto Segovia Ramírez

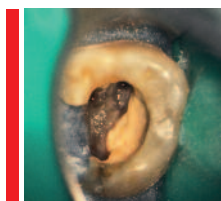
09



## Clinical case report of the use of Biodentine™ for deep caries treatment

Dr. Marianne Federlin, Birger Thonemann, Kerstin Galler, Wolfgang Buchalla, Regensburg

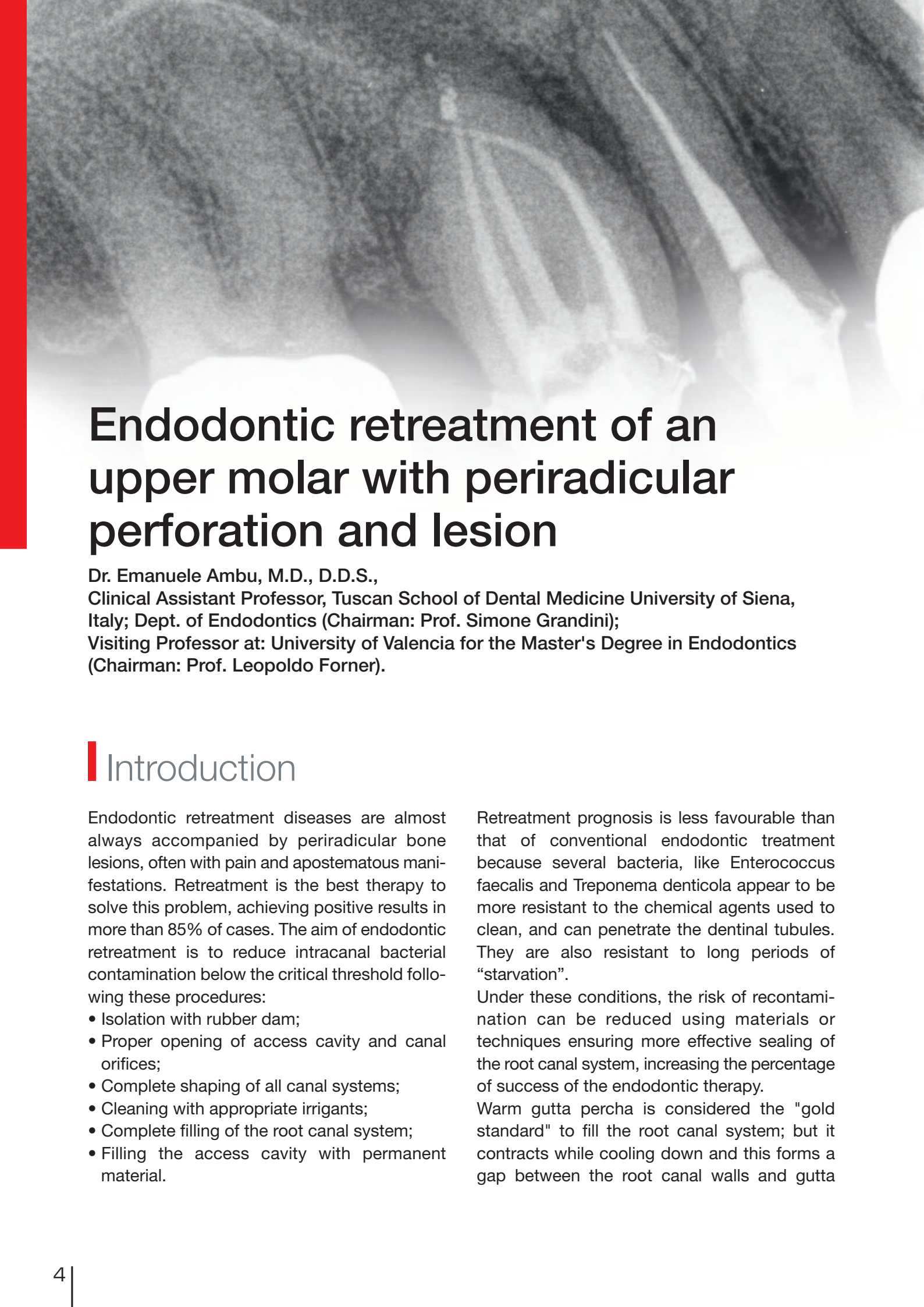
16



## Perforation repair with Biodentine™

Dr. Jaime Abarca Reveco

20



# Endodontic retreatment of an upper molar with periradicular perforation and lesion

Dr. Emanuele Ambu, M.D., D.D.S.,  
Clinical Assistant Professor, Tuscan School of Dental Medicine University of Siena, Italy; Dept. of Endodontics (Chairman: Prof. Simone Grandini);  
Visiting Professor at: University of Valencia for the Master's Degree in Endodontics (Chairman: Prof. Leopoldo Forner).

## Introduction

Endodontic retreatment diseases are almost always accompanied by periradicular bone lesions, often with pain and apostematous manifestations. Retreatment is the best therapy to solve this problem, achieving positive results in more than 85% of cases. The aim of endodontic retreatment is to reduce intracanal bacterial contamination below the critical threshold following these procedures:

- Isolation with rubber dam;
- Proper opening of access cavity and canal orifices;
- Complete shaping of all canal systems;
- Cleaning with appropriate irrigants;
- Complete filling of the root canal system;
- Filling the access cavity with permanent material.

Retreatment prognosis is less favourable than that of conventional endodontic treatment because several bacteria, like *Enterococcus faecalis* and *Treponema denticola* appear to be more resistant to the chemical agents used to clean, and can penetrate the dentinal tubules. They are also resistant to long periods of "starvation".

Under these conditions, the risk of recontamination can be reduced using materials or techniques ensuring more effective sealing of the root canal system, increasing the percentage of success of the endodontic therapy.

Warm gutta percha is considered the "gold standard" to fill the root canal system; but it contracts while cooling down and this forms a gap between the root canal walls and gutta

percha so that the bacteria of dentinal tubules can contaminate canals again.

To solve this problem, a cold-filling technique based on bioceramics has been recently introduced. This material was initially suggested to replace mineral trioxide aggregate in various cases (radicular perforations, apexifications, direct capping of the pulp, etc.), because MTA had some problems: it took long to harden and it was unsuitable to be in touch with the oral environment.

## Clinical Case

A male Caucasian patient VL aged 48 was referred by a colleague who did not manage to probe the root canals, after many attempts, had not succeeded in probing the canals of his right upper molar, which had been unadequately filled during previous treatments. There was also a perforation altering the pathway of the mesio-vestibular canal. The clinical picture was further complicated by two vestibular fistulae secreting pus. Endoral RX and CBCT examination (*Fig. 1*) -- performed to better understand the functioning of root canals -- showed widespread periradicular lesions and an inflammation of the male breast, with likely odontogenous origin.

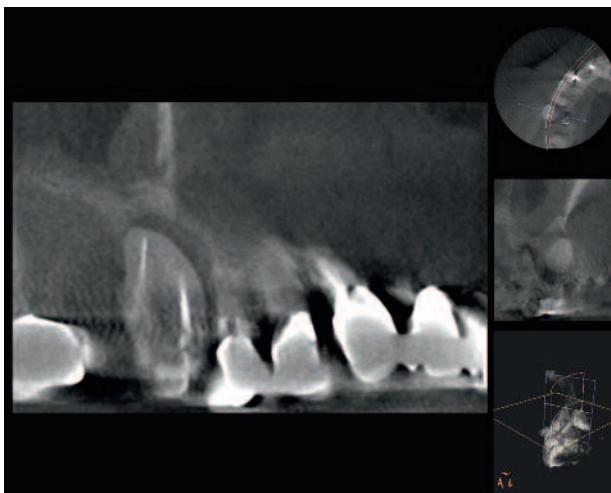


Fig. 1

More recently, a new preparation has permitted the use of bioceramics as an endodontic filling material.

The aim of this paper is to describe a complex example of molar retreatment treated by means of BioRoot™ RCS, a canal filling material sold by Septodont (Saint-Maur-des-fossés, France).

While the palatal and mesio-vestibular canals were easily renegotiable, it was not possible to restore the correct course of the mesio-vestibular canal. Using a surgical microscope, it was possible to locate the orifice of the mesio-palatal canal (*Fig. 2, arrow*), not detected in the two preceding treatments. This canal was found to be confluent with the mesio-vestibular, thus permitting recovery of the entire course, which appeared anomalous compared to the usual endodontic anatomy of the first upper molar. Following a thorough cleaning of the root canal system, the practitioner filled the entire system using cold tapered gutta percha points (06) and

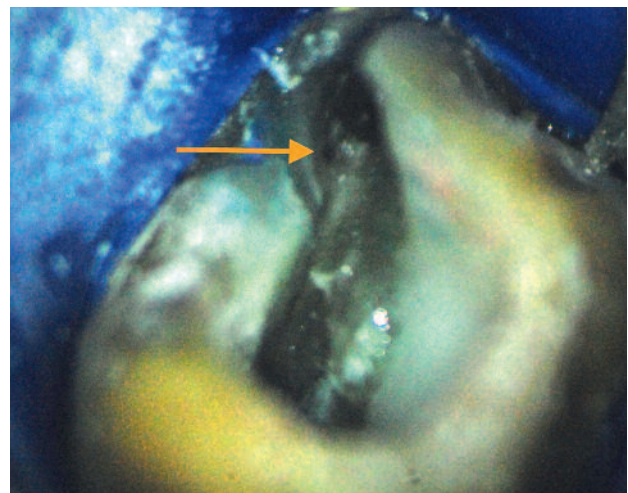
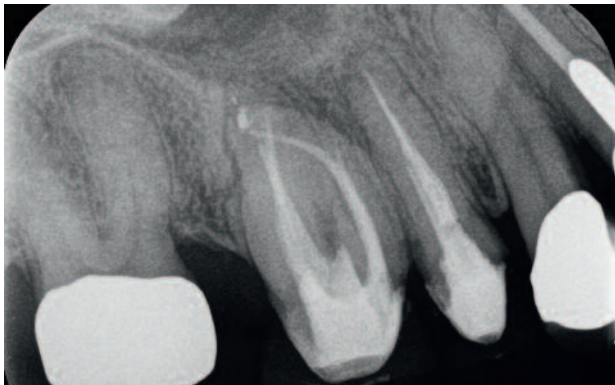

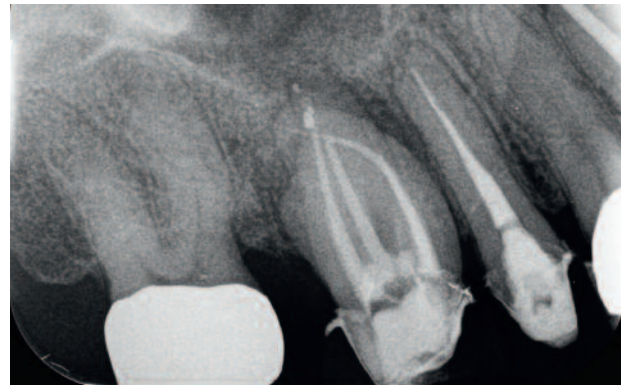Fig. 2

BioRoot™ RCS cement (*Fig. 3*). The control after seven months showed that the periradicular lesion had almost disappeared and the



*Fig. 3*

renewed pneumatisation of the maxillary sinus (*Fig. 4*). Subsequent examination is anticipated 12 months after completion of treatment.



*Fig. 4*

## Discussion

Bioceramics are today quite well-known materials in the literature, especially because they can replace mineral trioxide aggregate.

Biodentine™, defined as an active biosilicate, is bioactive and continues to produce hydroxyapatites long after blending. It can therefore fit the dentinal walls and improve its sealing capacity. BioRoot™ RCS -- a product obtained after testing these materials -- can ensure complete sealing of the root canal system after full cleaning and shaping. It is also an effective antibacterial agent. Its biocompatibility has been recently evaluated in several studies, but there is no research published about the clinical effects of this material. It is a very interesting material because it perfectly adheres to both dentine and gutta percha, so that it can be used in cold sealing techniques.

## Conclusion

The case described above shows how it is possible to have excellent canal filling even in anatomically complex or compromised situations. Thanks to the excellent sealing capacity of bioceramics the periradical tissues can recover

This cannot be considered a monocone technology: in this technique, a single gutta percha cone is inserted into the canal -- which has [already] been filled with endodontic cement -- in an attempt to occupy the major part of the volume of the root canal. Since the endodontic cement is absorbable with time, this technology was [traditionally] considered highly ineffective, and not recommended by many practitioners. On the other hand, in cold sealing technology using bioceramics, the cement plays an important role because it is truly active in sealing the canal. The gutta percha cone -- which must be inserted quite deeply, near the apex -- is the only material which permits retreatments in the event of technical errors.

rapidly. Prospective clinical studies must in any case be conducted to evaluate the effectiveness of this technique, both in the medium and the long term.



**Author:**

**Dr. Emanuele Ambu**

1989, Graduated from Medicine and Surgery at the University of Bologna;  
1998, Attend advanced post-graduate courses at the University of Florence.  
2002-2003, Teaching of dental subjects at the University of Modena-Reggio Emilia  
2005-2006, Coordinator of the Post-graduate Course in endodontics  
2006-2008, obtain Master Degree in Endodontics at the University of Bologna  
2011-2013, visiting professor at the Tuscan School of Medicine, University of Siena.  
2013, visiting professor at the University of Cagliari.

Dr. Emanuele Ambu is currently (2016) a visiting professor in the teaching of “Retrograde Endodontics” at the Tuscan School of Medicine, University of Siena. He is also a visiting professor for the Master's Degree in Endodontics and the Master's Degree in Endodontics at the Universitat de Valencia.

Dr. Emanuele Ambu has published various articles on endodontic subjects for both Italian and international journals. He is a reviewer for the journal International Journal of Pediatric Dentistry, [as well as] for the journal *Advances in Radiology* and for the site Online Endo Academy. Speaker in courses and congresses in Italy and foreign countries since 1995. He works in his independent praxis in bologna as an endodontist and oral surgeon.

**Download the complete series**

*Septodont*  
**Case Studies**  
*Collection*

[www.septodont.com](http://www.septodont.com)

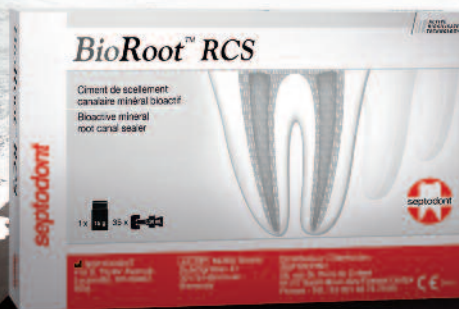

OBTURATION  
INNOVATION

# BioRoot™ RCS

Root Canal Sealer

High seal, and much more



We know that failure of a root canal treatment can have severe consequences for you and your patients.

With BioRoot™ RCS, move to a new generation of mineral obturation offering you an innovative combination of features:

- High Seal
- Antimicrobial properties
- Promotes peri-apical healing
- Easy obturations and follow-up

**ACTIVE  
BIOSILICATE  
TECHNOLOGY**

**BioRoot™ RCS. Succeed.**





# Retrofilling with Biodentine™ in apicoectomy

C.D.E.E Alberto Segovia Ramírez  
Dental Surgeon, Universidad Autónoma de Nuevo León, Master in Endodontics,  
Universidad Autónoma de San Luis Potosí

## Abstract

**Introduction:** apicoectomy is a complex surgical procedure undertaken in order to eliminate the etiology and enucleate the lesion in an affected tooth; a proper diagnosis is important in the development of a proper treatment plan and a favorable prognosis. Frank proposes that apicoectomy indications should be divided into three groups. **Methods:** This case report describes the surgical treatment of a tooth with a history of root canal treatments associated with chronic periapical lesion; the surgical approach taken

was an apicoectomy with retrofilling, and a xenograft was implanted. **Discussion:** The results were favorable because the symptoms and apical lesion presented by the patient disappeared, and the tooth was preserved. The lesion was sent in for histopathology, which showed apical granuloma ICD/WHO CODE 10: K04.5. **Conclusion:** pure tricalcium silicate (Biodentine™) is an ideal material for use in Apicoectomy with retrofilling due to its characteristics of biocompatibility and apical sealing capacity.

## Introduction

Periapical surgery is a surgical procedure used to treat teeth with periapical lesions that cannot be resolved using conventional endodontic treatments (root canal treatment or retreatment). It

must allow the curettage of the pathological periapical tissue, apicoectomy of the affected root, and good retrograde sealing of the dental canal.<sup>(1)</sup>

Indications: We follow the criteria proposed by Frank, grouping indications into 3 categories:

- 1.- surgery due to technical errors
- 2.- surgery due to dental anomalies
- 3.- surgery due to dental pathology<sup>(2)</sup>

Diagnosis: In most cases, analysis of the data obtained from anamnesis, physical examination, and radiology allow for an accurate diagnosis. Some cases may resist an accurate diagnosis; diagnosis may thus be presumptive<sup>(2)</sup>

Pulp vitality tests make it possible to distinguish radicular cysts from other non-endodontic periapical pathologies (cementomas, globulomaxillary cysts) where the vitality of the pulp itself is preserved, while also differentiating the teeth that are affected by the cystic pathology and those that are not. Radiologically, it is not possible to establish an absolute and objective distinction between a radicular cyst and an apical granuloma.<sup>(3)</sup>

A lesion that is clinically and radiographically suspected to constitute a cyst must undergo surgical treatment. The choice of a specific surgical method depends heavily on radiological

examination, which defines the extent and relations of the cystic lesion with the neighboring organs.<sup>(3)</sup>

During the procedure, between 2 to 3 mm should be resected, and a retrograde cavity performed with ultrasound and subsequently obturated, since statistically this shows greater success than simple apicoectomy<sup>(4)</sup>. It is also necessary to choose the right materials for use in the retrofilling procedure<sup>(5,6)</sup>.

We have studied the benefits of using pure tricalcium silicate (Biodentine™) as compared with Mineral Trioxide Aggregate (MTA), as it presents greater biostimulation<sup>(7)</sup>. Garrido M. presents a study of biocompatibility for pure tricalcium silicate, comparing it with Mineral Trioxide Aggregate and zinc oxide-eugenol in subcutaneous tissues. They demonstrated the biocompatibility of pure tricalcium silicate, after 14 days with mild to negligible inflammation<sup>(8)</sup>. Furthermore the use of guided tissue regeneration, membranes, and grafting in this type of surgery facilitates regenerative processes relative to the alterations caused by the periapical disease and its sequelae<sup>(9)</sup>.

## Clinical case

Female patient, 25 years of age, presented for endodontic consultation on March 7, 2016. The patient reported pain upon chewing in the left central incisor (OD 21), with a history of root canal treatment at 8 years old.

First appointment: Physical examination: swelling was observed in the left genian area; upon exploration of the soft tissue inflammation and flushing were observed in the apical area of tooth 21. Upon palpation of the gingiva buccal to the maxilla at tooth 21 a sharp pain was felt, and sharp pain presented as well upon horizontal and vertical percussion; pulp vitality tests were conducted on the teeth adjacent to tooth 21 to assess the absence of devitalization in these teeth. Radiographic exploration: Tooth 21 was observed, with root canal treatment, without apicogenesis. Radiolucent unilocular lesion,

apical third well-defined, diameter of 5 mm; tooth presents a crown-root ratio of 1:1 (Fig. 1).

Presumptive diagnosis: Chronic Non-suppurative Apical Periodontitis.

Second appointment: Occlusion was assessed in tooth 21, which

presented attrition due to bruxism and the presence of loose high class (class 4) resin in the mesio-incisal. The treatment plan was determined with a reserved prognosis for tooth 21. Anesthesia was applied using 3% Mepivacaine, and isolation conducted with a rubber dam at

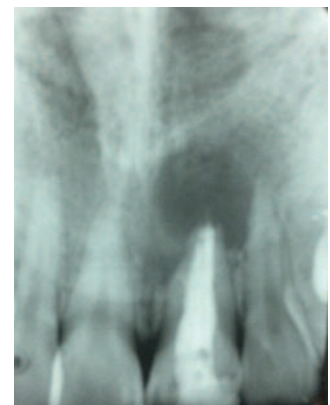

Fig. 1: Initial radiography.

tooth 21; the resin was eliminated from tooth 21; the gutta-percha was removed from the cervical third of the root; the canal was cleaned with hypochlorite 5%; the canal was then dried. A type 2 resin-modified ionomer was then placed in the cervical third of the canal, and we proceeded to reconstruct the tooth using resin incrementally; the resin was then polished and a periapical tomography conducted (Fig. 2). Third appointment: Disinfection of teeth and mucous membranes was performed with an oral antiseptic, and anesthesia performed with mepivacaine 3%. A triangular flap was created from tooth 22

to tooth 11 using a #15 scalpel blade (Fig. 3 and 4). At the time of flap elevation, the epithelium was found to be integrated with the mucosa and submucosa; maintaining tension on the flap, the knife blade was placed parallel to the bone surface, and the flap was lifted without perforating the mucosa; once the trajectory was dissected we proceeded with the flap elevation (Fig. 5 and 6). Curettage cleaning was performed with a Lucas curette, and while irrigating with saline solution, the foreign body excision process was conducted apical to tooth 21 (Fig. 7, 8, 9 and 10). Subsequently, the inflamed tissue was sent in

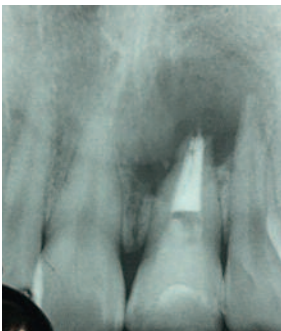

Fig. 2: Radiography with placement of Resin-Modified Glass Ionomer.

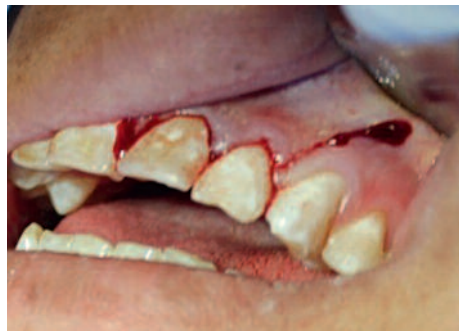

Fig. 3: Triangular flap incision.

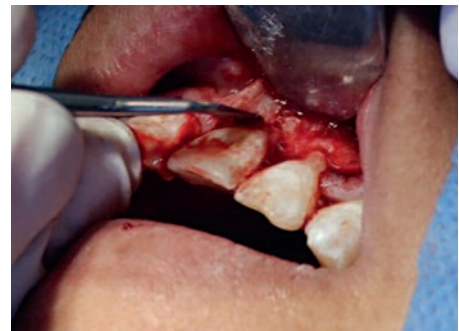

Fig. 4: Flap elevation.

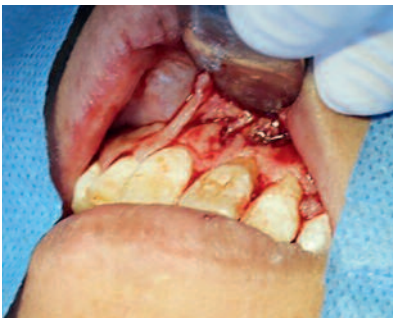

Fig. 5: Granulomatous tissue observed.

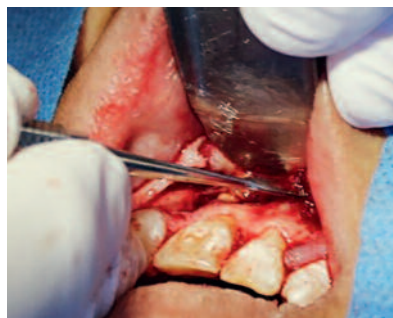

Fig. 6: Separation of granulomatous tissue from flap.

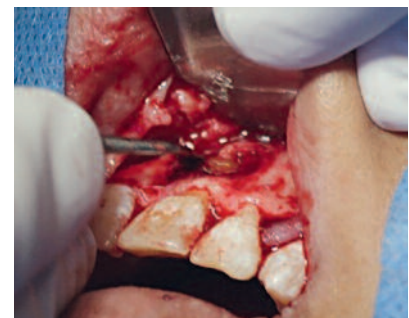

Fig. 7: Excision of inflamed tissue.

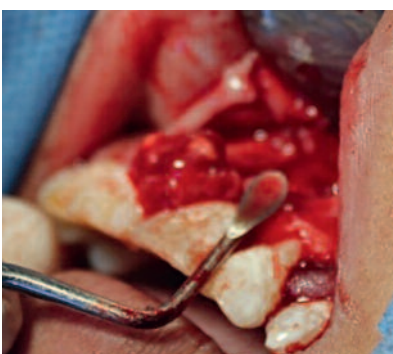

Fig. 8: Excision of inflamed tissue.

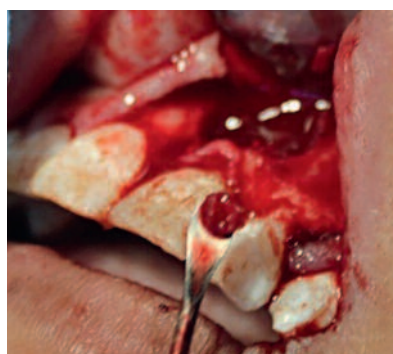

Fig. 9: Cleaning and excision of inflamed tissue.

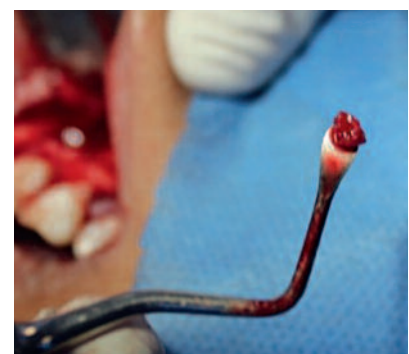

Fig. 10: Cleaning and excision of inflamed tissue.

for histopathological examination, and we proceeded to conduct the resection of the apical third, removing 3 mm with a 0° tapered diamond bur. (Fig. 11). A retrograde cavity was prepared using ultrasound, removing 3 mm of gutta-percha apically (Fig. 12 and 13). The area was then washed with saline, and the cavity dried with paper points; and retrograde cavity access was inspected to ensure the complete removal of gutta-percha from the canal walls apically to

a depth of 3 mm for obturation with Biodentine™ (Fig. 14 and 15).

One capsule of (Biodentine™) was prepared for 30 seconds, and was placed in the retrograde cavity using a thin carrier (Fig. 16, 17, 18 and 19). Lyophilized bone was placed in saline in a sterile glass dish for 20 minutes; the osseous defect was subsequently filled with bone, free of any pathological tissue, apical to tooth 21 (Fig. 20). The collagen membrane was then placed over

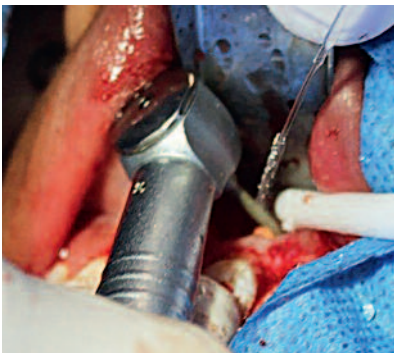

Fig. 11: Apical resection with diamond bur.

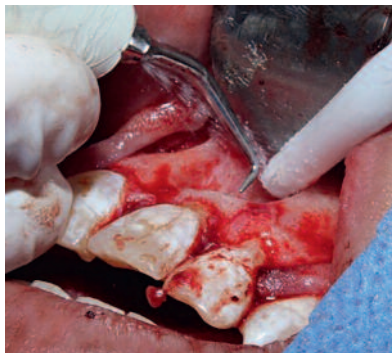

Fig. 12: 3 mm retrograde cavity with ultrasound.

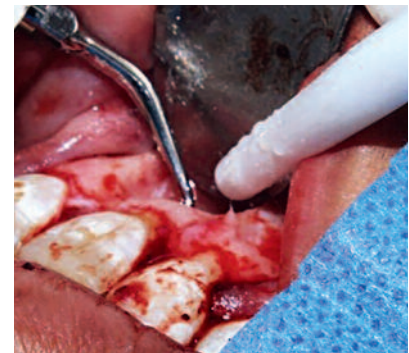

Fig. 13: 3 mm retrograde cavity with ultrasound.

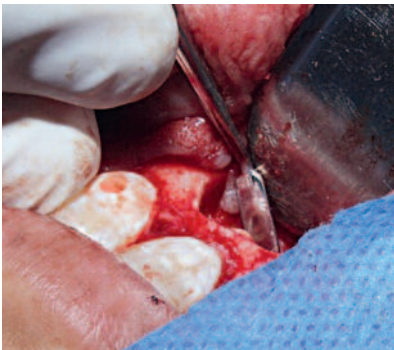

Fig. 14: 3 mm retrograde cavity observed.

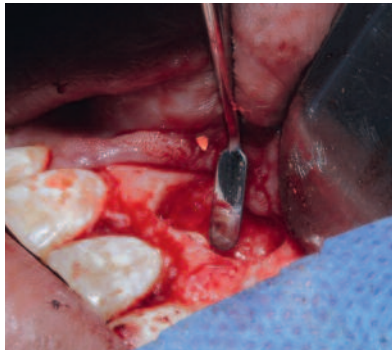

Fig. 15: 3 mm retrograde cavity observed.



Fig. 16: Preparation of pure tricalcium silicate (Biodentine™) 30 sec.

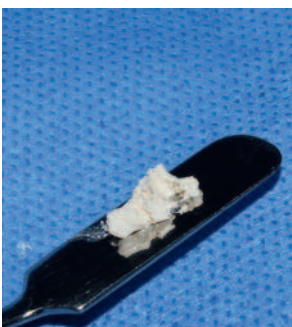

Fig. 17: Tricalcium silicate (Biodentine™).

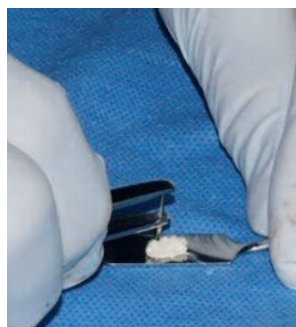


Fig. 18: Carrier for pure tricalcium silicate.

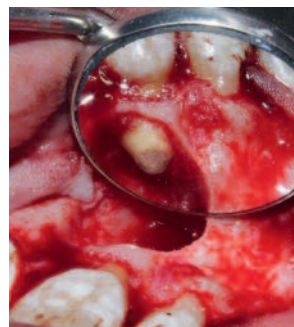

Fig. 19: Retrograde filling with (biodentine™).

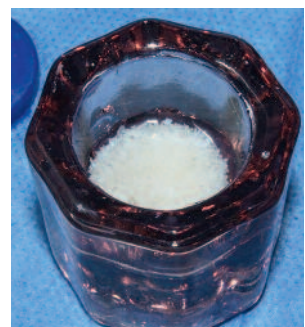


Fig. 20 : Lyophilized xenograft bone in saline solution for 20 min.

the xenograft (Fig. 21) and sutured with simple stitches using "000" silk (fig. 22, 23, 24 and 25). A final periapical radiograph was then taken (Fig. 26). Postoperative instructions were provided to the patient, prescribing the use of Amoxicillin with Clavulanic acid in 875/125 mg tablets, once

every 12 hours for 7 days, and sublingual ketorolac 25/10 mg tablets, once every 12 hours for 4 days.

Fourth appointment: The stitches were removed and we decided to completely remove tooth 21 from occlusion.

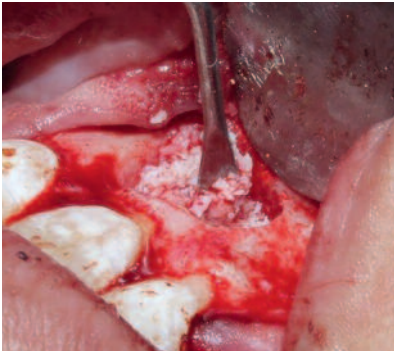


Fig. 21: Placement of xenograft in osseous defect.

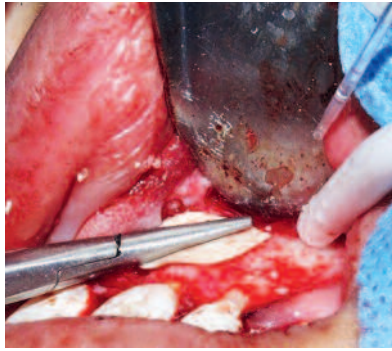


Fig. 22: Placement of collagen membrane.

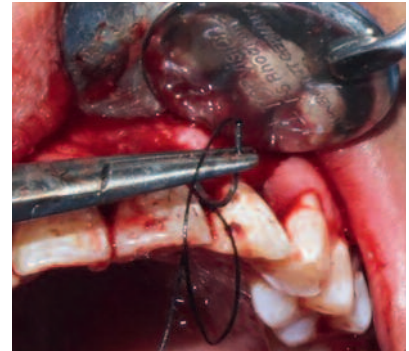

Fig. 23: "000" silk suture.

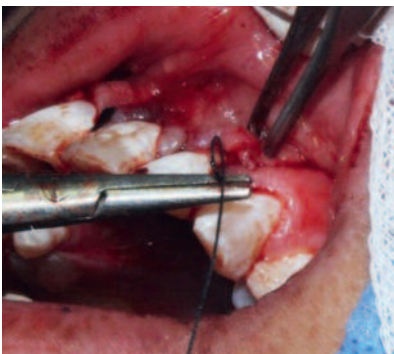


Fig.24 : "000" silk suture.

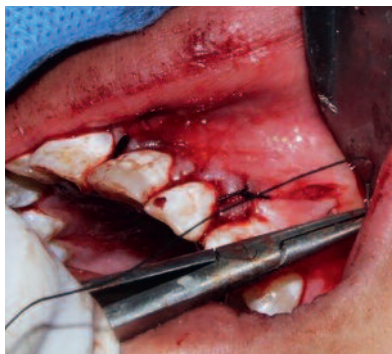

Fig. 25: "000" silk suture.

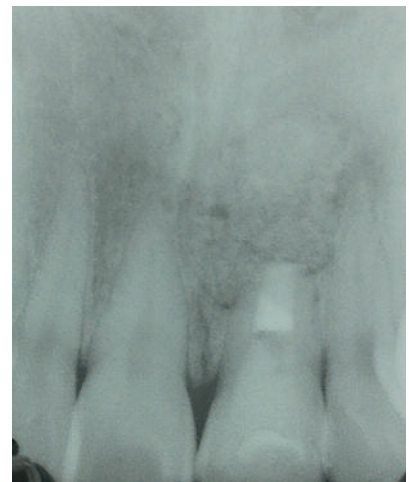

Fig. 26: Placement of collagen membrane.

## Discussion

The results were favorable because the symptoms and apical lesion presented by the patient disappeared, and the tooth was preserved.

### Histopathological diagnosis\*

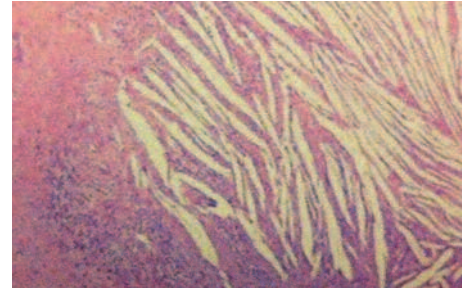
Macroscopic Description: two fragments of soft tissue were received in formaldehyde, irregularly shaped, lobed, brown-colored, with a hemorrhagic appearance. Together the fragments measured about 15 x 6 x 6 mm along their major axes (Fig. 27). The larger fragment was resected; it was solid when cut, and was included in its entirety in a capsule for processing and study by conventional technique, embedded in paraffin and stained with hematoxylin and eosin HE.

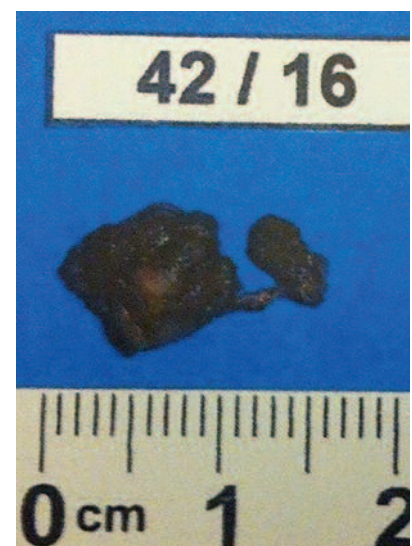

Fig. 27: Histopathological cross-section.

\*Performed by Dr. Marco Antonio Torres Carmona

Microscopic description: nine cuts were analyzed. The specimens studied were formed entirely of connective tissue presenting edema and diffuse infiltration by mononuclear leukocytes and epithelioid histiocytes. Towards the interior, countless cholesteric fissures were observed. A deposit was observed containing a granular foreign body of diffuse or intracytoplasmic distribution in histiocytes (*Fig. 28*), original magnification X100. / (*Fig. 29*) original magnification X400).

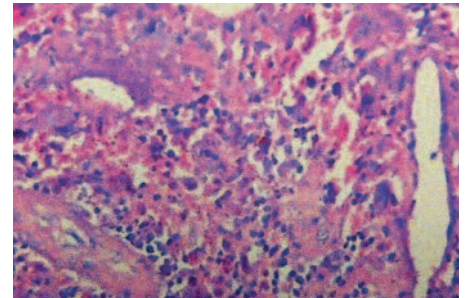


*Fig. 28:* Original magnification X 100.

**No malignancy was observed in the cross-sections studied.**

**Diagnosis:**

**apical granuloma. icd/who code 10: k04.5.**



*Fig. 29:* Original magnification X 400.

## Conclusion

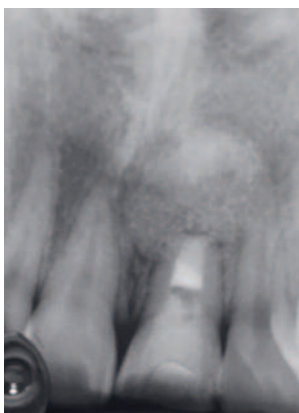Pure tricalcium silicate (biodentine™) meets the core characteristics for a retrofilling material, such as possessing a high degree of biocompatibility, not causing cytotoxicity or inflammation, and antibacterial activity as provided by a highly alkaline ph of 12.

Its other properties include biostimulation of the mesenchymal cells in the supporting periodontal tissues, which promote the regeneration of the periapical environment, not containing other materials like mta.

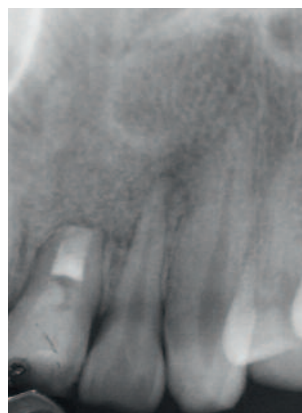
As regards mechanical characteristics, pure tricalcium silicate (biodentine™) is far superior to the other materials used for these treatments,

as it has a high degree of mechanical resistance (300 mpa at 30 days) thus preventing material rupture and bacterial infiltration.

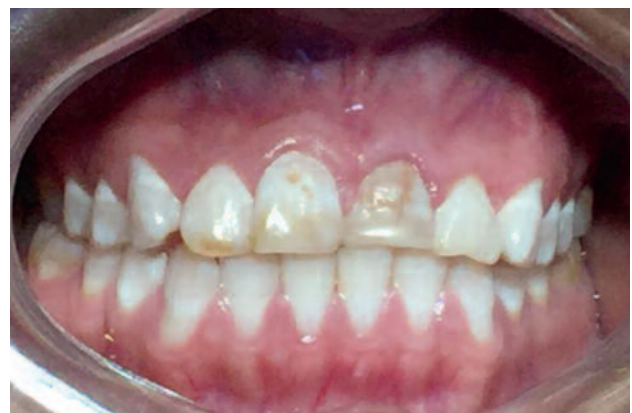Another important feature is the ease of handling of the powder and liquid, providing the clinician with enough time to place and adapt the material, which leads to a reduction in surgical operating time favorable to both the patient and surgeon. We can thus say that pure tricalcium silicate (biodentine™) is an ideal material for surgical endodontic operations.



RX control at 6 months



RX control at 6 months



Control at 6 months

**Author:****C.D.E.E Alberto Segovia Ramírez**

1996-1998 Master's in Endodontics from Faculty of Dentistry of the U.A.S.L.P. San Luis Potosí, S.L.P.Mexico.

1988-1993 Dental surgeon from Faculty of Dentistry of the U.A.N.L. Monterrey, N.L. México.

Certified as a specialist endodontist by the Mexican Council of Endodontics (no. 369) in May 2004, May 2009 and May 2014 in Mexico City D.F.

**Professional and teaching experience**

National Endodontics Research Prize from the Mexican Endodontics Association, 1999.

February-December 1997: Professor of Endodontics and Clinical Adviser in the undergraduate teaching staff at the Faculty of Dentistry of the U.A.S.L.P.

September 1998 - May 2003: Postgraduate Professor of Endodontics in the Dentistry Studies Center of Querétaro.

January 2001 to date: Professor of Endodontics at the Universidad del Valle de México (Querétaro campus).

Guest professor for postgraduate Endodontics at the Universidad San Carlos de Guatemala (Faculty of Dentistry) from 2003 to 2009.

President of the Scientific Committee of the Dentistry Association of Querétaro (2003-2005 and 2005-2007).

Private practice in Endodontics, from 1995 to date, in Monterrey, San Luis Potosí and Nuevo Laredo, and since 1998 to date in Querétaro.

## References

1. Peñarocha M, Peñarocha M. Atlas de cirugía periapical. . 1a ed. Barcelona España: editorial océano; 2014.
2. Canalda C, Brau E. Endodoncia Técnicas clínicas y bases científicas. 3ª ed. Barcelona España: Elsevier Masson; 2014.
3. García A, Bujaldón A, Rodríguez A. Lesiones periapicales. Diagnóstico y tratamiento [periapical lesions. diagnosis and treatment] [internet] Universidad Complutense de Madrid Medicina Bucal. Departamento de Estomatología. Universidad de Granada AVANCES EN ODONTOESTOMATOLOGÍA, Vol. 31, 31-42. 2015. [http://scielo.isciii.es/scielo.php?script=sci\\_arttext&pid=S0213-12852015000100005](http://scielo.isciii.es/scielo.php?script=sci_arttext&pid=S0213-12852015000100005)
4. Gómez V, Giner J, Maniegas L, Gaité J, Castro A, Ruiz J, "et all". Apicectomía quirúrgica: propuesta de un protocolo basado en la evidencia [Surgical apicoectomy: proposed evidence-based protocol.] [internet] Revista Española de Cirugía Oral y Maxilofacial, vol.33 no.2 Madrid, 2 pág. (Abr.-jun. 2011). [http://scielo.isciii.es/scielo.php?pid=S1130-05582011000200002&script=sci\\_arttext&tlng=e](http://scielo.isciii.es/scielo.php?pid=S1130-05582011000200002&script=sci_arttext&tlng=e)
5. Borisova T, Panov V, Peev S, Papanchev G. ROOT END FILLING MATERIALS REVIEW. Scientifica Medicinae Dentalis, Medical University of Varna. (2013). vol. 1, 1, 13-17.
6. Priyanka S. A Literature Review of Root-End Filling Materials IOSR Journal of Dental and Medical Sciences (IOSR-JDMS) e-ISSN: 2279-0853, p-ISSN: 2279-0861. Volume 9, Issue 4 (Sep.- Oct. 2013), PP 20-25 [www.iosrjournals.org](http://www.iosrjournals.org)
7. Correa M, Castrillón N. Comparación de microfiltración apicocoronal entre MTA y Biodentine™ en dientes unirradiculares. [Comparison of microfiltration apicocoronal between MTA and Biodentine™ in singlerooted teeth]. [Internet] Universidad San Francisco Quito; Publicado: 2015/03/01. [http://www.usfq.edu.ec/publicaciones/odontoinvestigacion/Documents/odontoinvestigacion\\_n001/oi\\_001\\_001.pdf](http://www.usfq.edu.ec/publicaciones/odontoinvestigacion/Documents/odontoinvestigacion_n001/oi_001_001.pdf)
8. Garrido G, Moraes L, Louzada D, Meneguccion L. and Rodrigues S. BIOCOMPATIBILITY EVALUATION OF BIODENTINE IN SUBCUTANEOUS TISSUE OF RATS. JOE. VOLUMEN 40, NUMBER 9, SEPTIEMBRE 2014.
9. Calzada-Bandomo A, Calzada-Bandomo A, Mora-Pérez C. Terapia periodontal regenerativa: antecedentes y perspectivas. Medisur [revista en Internet]. 2013 [citado 2016 Jun 23]; 11(5):[aprox. 8 p.]. Disponible en: <http://medisur.sld.cu/index.php/medisur/article/view/2360>.

# Clinical case report of the use of Biodentine™ for deep caries treatment

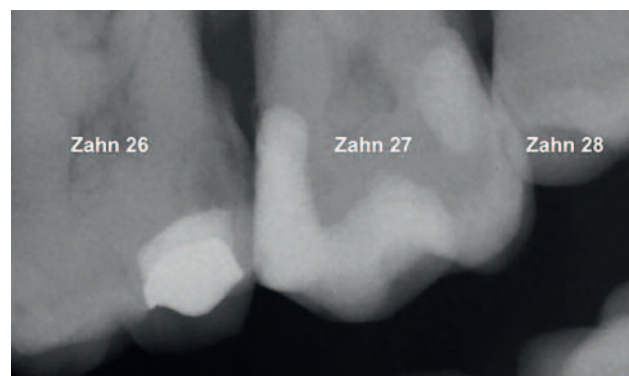
Marianne Federlin, Birger Thonemann, Kerstin Galler, Wolfgang Buchalla, Regensburg

## Biodentine™ for deep caries treatment/underfilling beneath a direct composite restoration for deep caries of tooth 26

Biodentine™ is a bioactive calcium silicate cement and is suitable as a dentin replacement material for a wide range of indications in dental therapy, both for restorative measures in the region of the tooth crown and for endodontic treatments. The indications for restorative measures include, in addition to treatment of exposed dentin (underfilling; deep caries treatment for extensive caries lesions), purely provisional treatment in the enamel and dentin regions as well as direct and indirect capping.<sup>1</sup> In the following case report, Biodentine™ was used for deep caries treatment and as an underfilling material as part of direct treatment of a class II cavity with a composite filling.

A 72-year-old patient presented to the Outpatient Clinic for Tooth Preservation and Periodontology of the University of Regensburg in October

2013 for a routine checkup. When the findings were recorded, radiographs were taken in the region of the second quadrant because approximal caries was suspected. In the region of tooth 26 distally, “deep caries” was diagnosed (*Fig. 1*), and an appointment for filling therapy was therefore scheduled.



*Fig. 1:* Radiograph: Approximal caries tooth 26 distally.



Sensitivity testing of tooth 26 to cold with dry ice was positive. Treatment was performed without local anesthesia at the patient's request. Before dissection, a rubber dam was placed onto teeth 24 to 27. From the occlusal aspect, access to the defect was first created using a rotary diamond bur with water cooling. The distal cavity region was dissected using oscillating instruments (SonicFlex, KaVo, Biberach) (Fig. 2). The cavity was created as delicately as possible. Caries excavation was then performed using round burs with visual control using a surgical microscope. The cavity was checked for residual caries multiple times during the course of the excavation by means of FACE (fluorescence-aided caries excavation, SIROinspect, Sirona, Bensheim).<sup>2</sup>

During complete caries removal, the pulp was not exposed (Fig. 3). A metal matrix (HaweToflemire matrix, Kerr Dental, Rastatt) was then inserted and wedged. The cavity was cleaned and dried.

Biodentine™ was mixed according to the manufacturer's instructions and applied in the region of the distal pulp wall using a small ball plugger (Dycal-Instrument) and adapted using a Heide-mann spatula. Biodentine™ was thus simultaneously used for deep caries treatment and for underfilling. After a 12-minute binding time for Biodentine™, the defect was restored using a composite filling (Fig. 4).

For filling therapy, Etch & Rinse adhesive (Excite, Ivoclar Vivadent, Schaan, Liechtenstein) was used in combination with a fine-particle hybrid composite (Tetric EvoCeram, Ivoclar Vivadent). After etching of the enamel with phosphoric

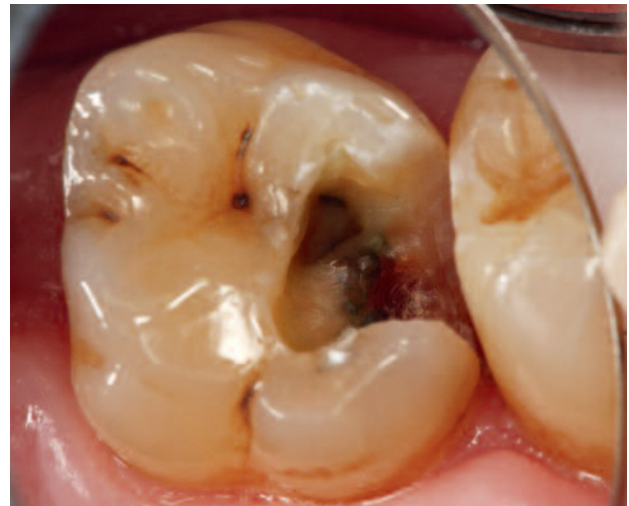

Fig. 2: Visualization of the defect.

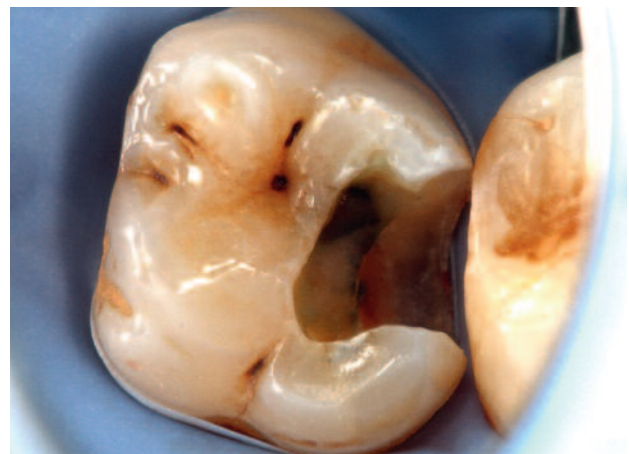

Fig. 3: Status post caries extraction, control by means of FACE.

acid (Total Etch, Ivoclar Vivadent) (Fig. 5) and application of the adhesive (Excite DC, Ivoclar Vivadent) (Fig. 6), the first layer, consisting of an opaque, flowable composite, was inserted into the cavity (Venus Flow Baseline, Heraeus Kulzer, Hanau). The cavity lining with a flowable composite facilitates good primary adaptation and

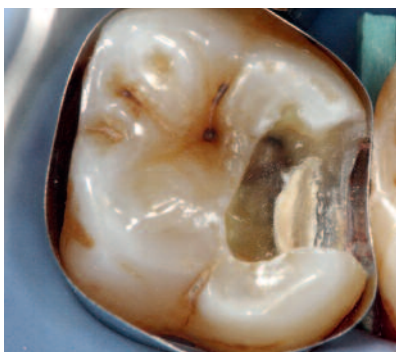

Fig. 4: Biodentine™ inserted as underfilling and for deep caries therapy.

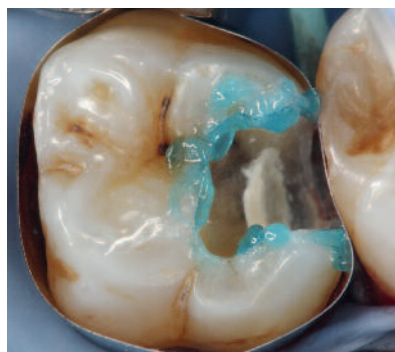

Fig. 5: Enamel etching with phosphoric acid.

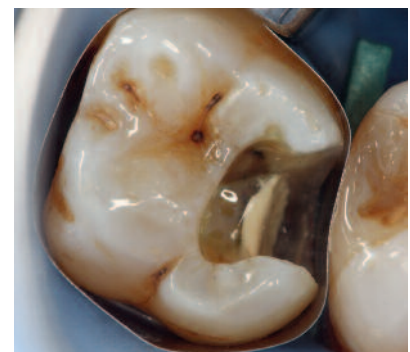
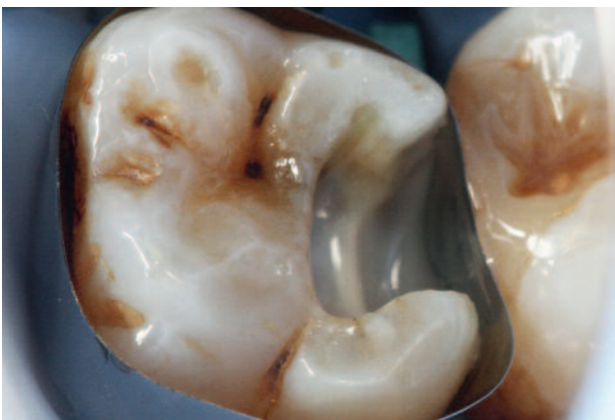
Fig. 6: Application of the adhesive system.

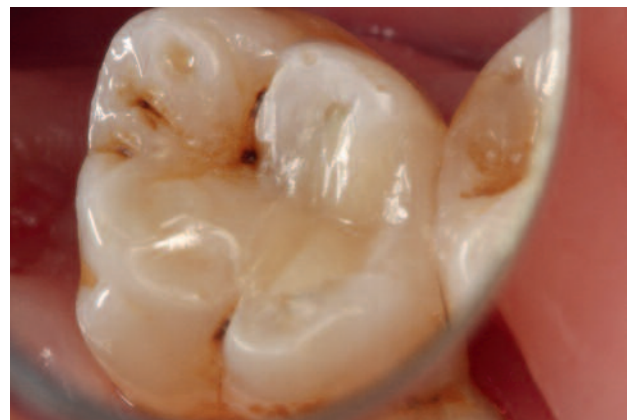stabilizes the bonding strength to dentin during the onset of the polymerization shrinkage of the composite that was placed next.<sup>3</sup> In addition, the opaque liner facilitates demarcation of the transition to the natural hard tooth structures (*Fig. 7*). The restoration was then constructed using an incremental technique. After removal of the rubber dam, occlusion and articulation were checked, and finishing and polishing (*Fig. 8*) were done using a fine-grit diamond bur.

In April 2014 (7 months after the deep caries treatment), the patient presented again for a dental examination. Tooth 26 still exhibited a positive reaction to sensitivity testing with dry ice. The patient did not report any postoperative hypersensitivity after treatment. Radiographs showed close adaptation of Biodentine™ to dentin; because of the similar radio-opacity of dentin and Biodentine™, it is not easy to distinguish between the two layers (*Fig. 9 and 10*). On the basis of the radiographs, there was no evidence of reactive tertiary dentin formation, as has also

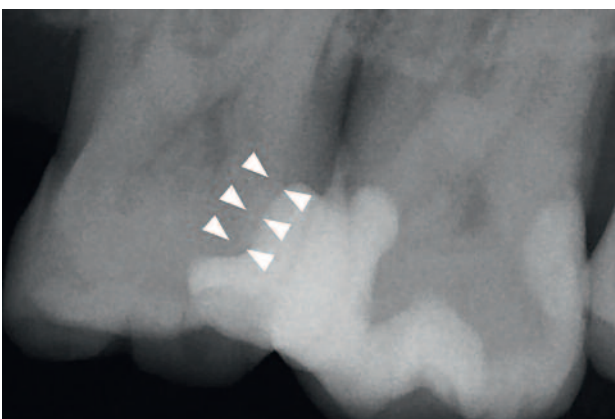
been reported in the literature for Biodentine™.<sup>1</sup> In this case, Biodentine™ was used as underfilling in terms of dentin replacement and for deep caries treatment. When the residual dentin strength is greatly reduced after caries excavation, microperforations to the pulp can be present. This can lead to direct contact of the components of the methacryl-based adhesive system with the pulp tissue, resulting – in the worst-case scenario – in irreversible damage to the pulp.<sup>4</sup> Therefore, in this case, Biodentine™ was used as an underfilling material because of its biological activity, on one hand, and for its dentin-like mechanical properties, on the other hand. Clinically, it was shown that the calcium-silicate cement, compared with other materials for deep caries treatment, can be applied without any pressure because of its consistency after mixing and can be adapted closely to the dentin and forms a mechanically stable barrier after binding. This was also evident in the radiographs taken after 7 months. A two-stage procedure was not indicated in this case.



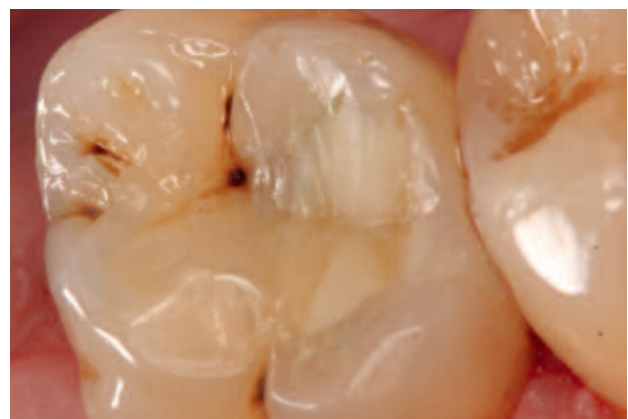*Fig. 7:* Insertion of an opaque flowable composite (lining technique).



*Fig. 8:* Composite filling.



*Fig. 9:* Radiograph 7 months after deep caries therapy: White arrow: dimensions of Biodentine™.



*Fig. 10:* Composite filling 7 months after deep caries therapy.

## References

---

- Septodont R&D Department: Biodentine™ - Active Biosilicate Technology: Scientific File.[http://www.septodont.fr/fichiers\\_upload/biodentinescientificfile.pdf](http://www.septodont.fr/fichiers_upload/biodentinescientificfile.pdf).
- Buchalla W, Lennon AM. Die fluoreszenzunterstützte Kariesexkavation - Funktionsprinzip und Empfehlungen für den Gebrauch. Oralprophylaxe und Kinderzahnheilkunde, 2013; 35 (4): 162–167.
- Haller B. Direkte Seitenzahnrestauration mit Komposit. Zahnmedizin up2date 6, 2009: 579–598.
- Schmalz G. Kompositkunststoffe: Lokale Toxizität und Gewebeverträglichkeit - Pulpreaktionen. In: Biokompatibilität zahnärztlicher Werkstoffe Hrsg.: G. Schmalz, D. Arenholt-Bindslev, Elsevier GmbH, Urban & Fischer Verlag, 2005 München, S. 111–115.



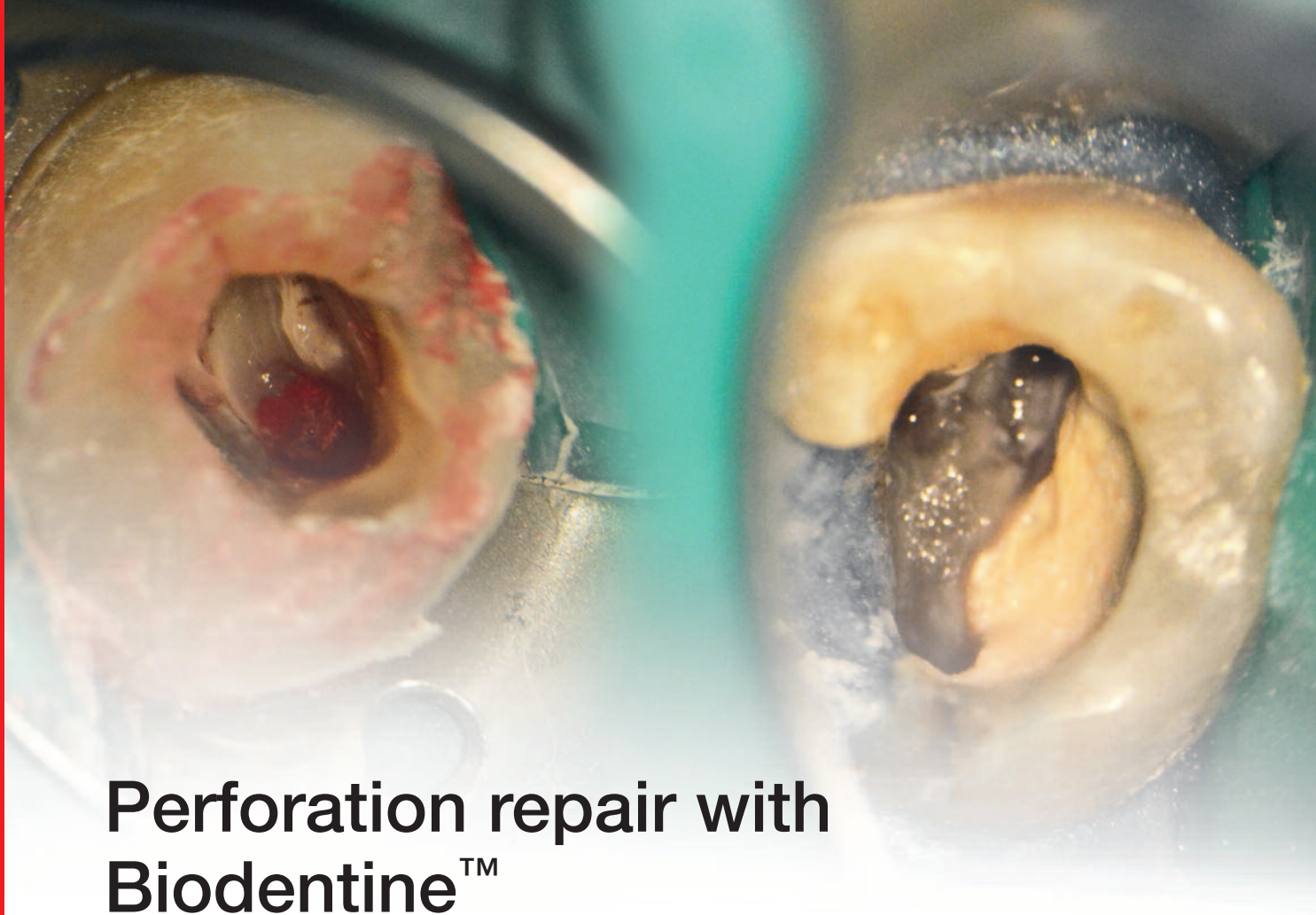**Author:**

**Priv.-Doz. Dr. med. dent. Marianne Federlin**

1980-1985 Studies in dentistry in Gießen, 1986-1988 Resident in independent practice, since 1988 scientific staff member at the Outpatient Clinic for Tooth Preservation and Periodontology, Hospital of the University of Regensburg (Director: Prof. Dr. W. Buchalla), 1992 Graduation (Edge quality of Cerec restorations in vitro), since 1993 Senior Physician, 2009 Postdoctoral thesis (Micromorphology of the binding zone and adhesive bond to root canal dentin); Scientific focus: ceramics – adhesive systems – adhesive bond to root canal dentin.

**Address for correspondence:**

University Hospital of Regensburg  
Center for Dental and Oral Medicine  
Outpatient Clinic for Tooth Preservation and Periodontology  
PD Dr. Marianne Federlin  
Franz-Josef-Strauß-Allee 11  
93053 Regensburg  
Telephone 09 41/9 44-60 20  
E-mail [marianne.federlin@klinik.uni-regensburg.de](mailto:marianne.federlin@klinik.uni-regensburg.de)



## Perforation repair with Biodentine™

Dr. Jaime Abarca Reveco  
MSc DDS and Endodontics Specialist

A perforation is an artificial communication between the root canal system and the tooth support tissue. This communication may occur due to dental hard tissue reabsorption, caries or by iatrogenic endodontic therapy.<sup>1</sup> Pulp chamber floor perforation is a iatrogenic complication that can be produced during access preparation or in the instrumentation of the cervical third of the root canal, causing endodontic failure.<sup>2</sup> It can also cause an inflammatory response of the periodontal tissue that may lead to an irreversible loss of periodontal insertion in the affected area.<sup>3</sup> The reparation procedure will be determined by the perforation position and the area involved. Treatment can be with or without surgery and the prognosis is usually excellent if the problem is correctly diagnosed and repaired, using a material that gives proper sealing and is biocompatible.<sup>2</sup>

Various materials have been used for root repair,

including silver amalgam, zinc oxide–eugenol, calcium hydroxide, composites, and glass ionomers. However, none of them are ideal for the special conditions and requirements of this type of treatment.<sup>4</sup> An ideal material should be biocompatible, dimensionally stable, insoluble, radiopaque, allow easy manipulation and placement and provide a proper seal.<sup>5</sup>

Biodentine™ (Septodont, Saint Maur des Fosses, France) is a high-purity calcium silicate–based material composed of tricalcium silicate, calcium carbonate, zirconium oxide, and a water-based liquid containing calcium chloride as the setting accelerator and water-reducing agent. Biodentine™ is recommended as a dentin substitute under resin composite restorations and as an endodontic repair material because of its good sealing ability, high resistance to compressive strength, short setting time, biocompatibility, bioactivity, and biomineralization properties.<sup>6</sup>

# Case Report

A male patient of 48 years of age was referred because of failure to locate the buccal canals of the 2.6 tooth. (Fig. 1).

**Clinical Examination:** A tooth with endodontic access and temporary filling is observed. It is unresponsive to thermal testing, and presents pain to both vertical and horizontal percussion and also to palpation in the palatal area next to the gingival margin.

**Diagnosis:** Apical Symptomatic Periodontitis with Previously Initiated Therapy.

**Treatment:** On the first appointment, the temporary filling is removed and a distopalatal perforation in the cameral floor becomes visible. (Fig. 2 and 3) The periodontal hemorrhaging under the perforation was stabilized using Calcium Hydroxide mixed with Propylene Glycol. Immediately after, the Palatal Canal is located (Fig. 4) and previous to the localization of the buccal canals, the perforation is blocked with a gingival barrier. (Fig. 5) Once the buccal canals are located, all canals are prepared with reciprocating rotary files. The perforation is sealed using Biodentine™ (Fig. 6) and an intracanal dressing of Calcium Hydroxide is left in place for 15 days.

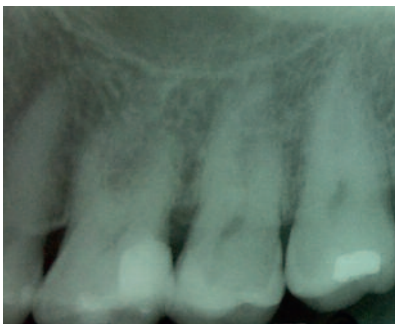

Fig. 1: Preoperative Radiograph.

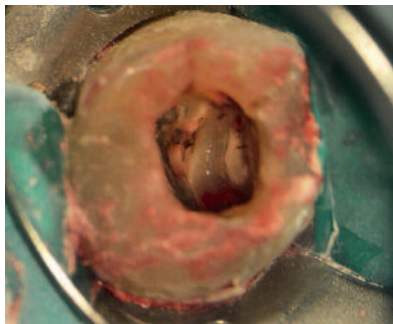


Fig. 2: DP perforation.

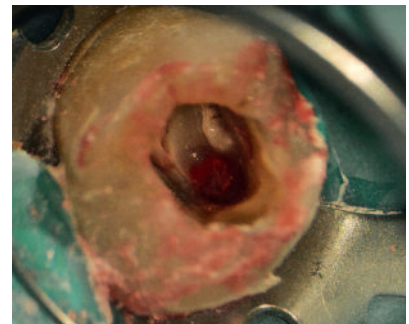


Fig. 3: DP perforation.

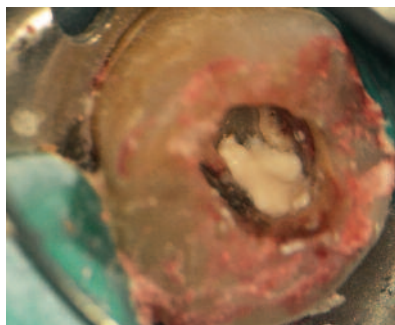


Fig. 4: Periodontal tissue stabilization and Palatal canal localization.

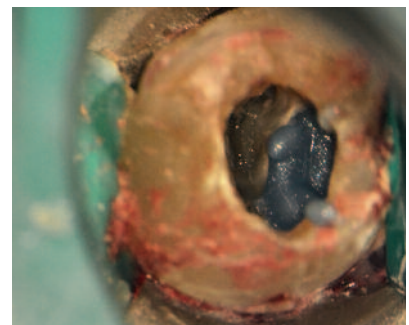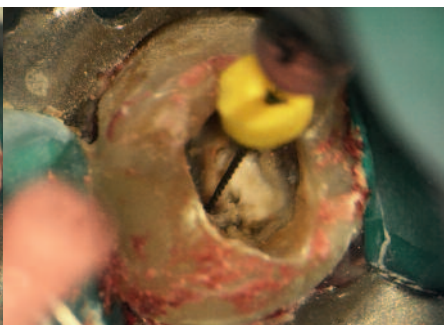


Fig. 5: Perforation blockage using gingival barrier.

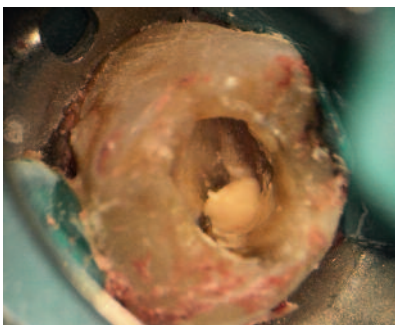


Fig. 6: Biodentine™ placement.

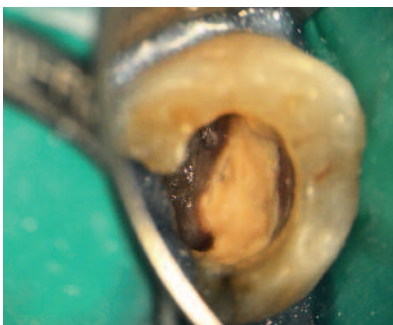


Fig. 7: Biodentine™ seal appearance on the second appointment

To the second appointment the patient arrives with a distopalatal cusp fracture. After tooth isolation and temporary filling removal, the Biodentine™ was observed to be hard and stable. (Fig. 7) A final irrigation protocol was performed with 5% Sodium Hypochlorite and 17% EDTA using sonic passive activation and the canals were obturated using a heat carrier. (Fig. 8) A double-seal temporary filling of Calcium Sulfate and Glass Ionomer is placed and the patient is referred back to his practitioner for definitive restoration.

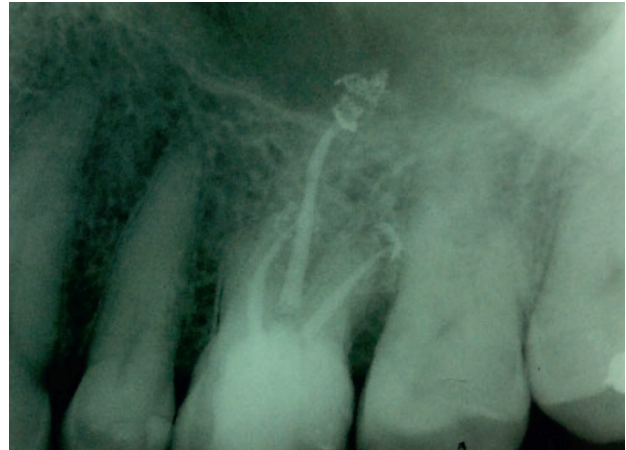

Fig. 8: Postoperative Radiograph.

## Conclusion

Biodentine™ proved to be a clinically reliable material in the reparation of pulp chamber floor perforations. It is biocompatible, like the well studied MTA, but with improved mechanical resis-

tance, making it an ideal material to endure occlusal forces in cases with large losses of hard tissue that occur during the search of a root canal.



### Author:

#### Dr. Jaime Abarca Reveco

MSc DDS and Endodontics Specialist

Coordinating Teacher of the Endodontics Graduate Program in San Sebastian University

Teacher in the Rehabilitation Department of the Undergraduate Program at San Sebastian University

Active Member of the Chilean Endodontics Society

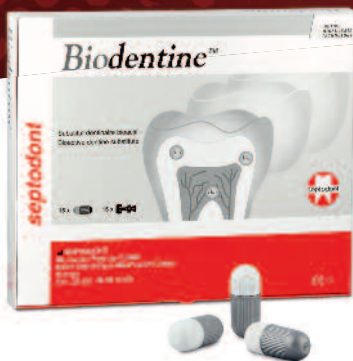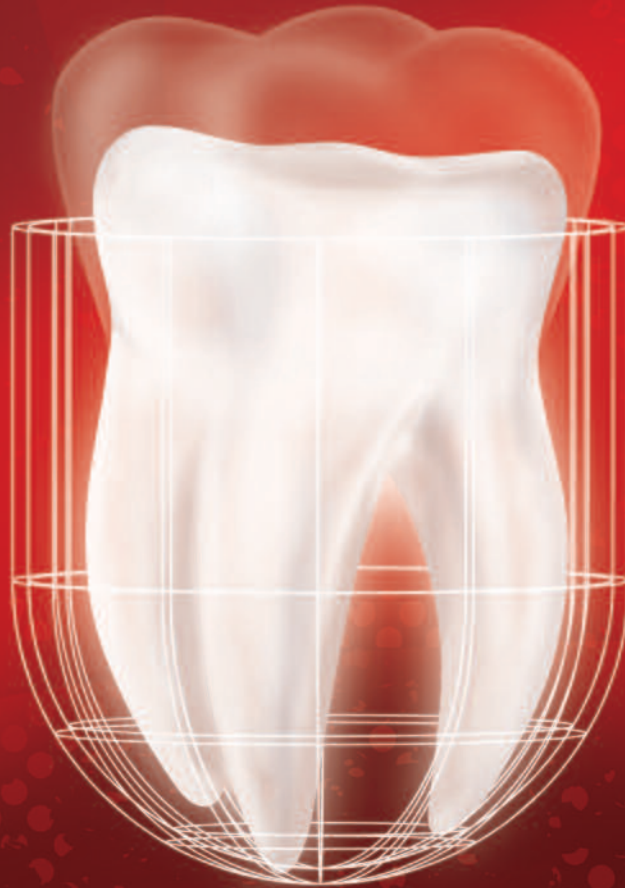Member of the AAE

## References

- 01 Lodiene G, Kleivmyr M, Bruzell E, Orstavik D. Sealing ability of mineral trioxide aggregate, glass ionomer cement and composite resin when repairing large furcal perforations. *British dental journal*. 2011;210:E7. Epub 2011/03/12.
- 02 da Silva EJ, Andrade CV, Tay LY, Herrera DR. Furcal-perforation repair with mineral trioxide aggregate: Two years follow-up. *Indian journal of dental research : official publication of Indian Society for Dental Research*. 2012;23:542-5. Epub 2012/12/22.
- 03 Samiee M, Eghbal MJ, Parirokh M, Abbas FM, Asgary S. Repair of furcal perforation using a new endodontic cement. *Clinical oral investigations*. 2010;14:653-8. Epub 2009/11/06.
- 04 Zhou HM, Shen Y, Wang ZJ, Li L, Zheng YF, Hakkinen L, Haapasalo M. In vitro cytotoxicity evaluation of a novel root repair material. *Journal of endodontics*. 2013;39:478-83. Epub 2013/03/26.
- 05 Aggarwal V, Singla M, Miglani S, Kohli S. Comparative evaluation of push-out bond strength of ProRoot MTA, Biodentine, and MTA Plus in furcation perforation repair. *Journal of conservative dentistry : JCD*. 2013;16:462-5. Epub 2013/10/02.
- 06 Guneser MB, Akbulut MB, Eldeniz AU. Effect of various endodontic irrigants on the push-out bond strength of biodentine and conventional root perforation repair materials. *Journal of endodontics*. 2013;39:380-4. Epub 2013/02/14.

# Biodentine™

The first and only dentin in a capsule



ACTIVE  
BIOSILICATE  
TECHNOLOGY

As the **first all-in-one** biocompatible and bioactive **dentin substitute**, Biodentine™ fully replaces dentin wherever it's damaged.

Biodentine™ helps the remineralization of dentin, preserves the pulp vitality and promotes pulp healing. It replaces dentin with similar biological and mechanical properties.

Improving on **Biodentine™** clinical implementation, you can now bond the composite onto Biodentine™ in the same visit and perform the **full restoration in a single session**.

To enjoy the clinical benefits of the first and only dentin in a capsule, ask your dental distributor for Biodentine™.



Learn more with  
the Biodentine™ brochure





The Dental Pharmaceutical Company

---

INNOVATIVE, SAFE AND EFFECTIVE SOLUTIONS FOR DENTISTRY WORLDWIDE