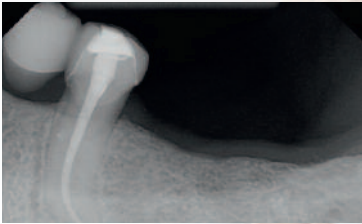


Septodont Case Studies *Collection*

No. 16 - November 2017

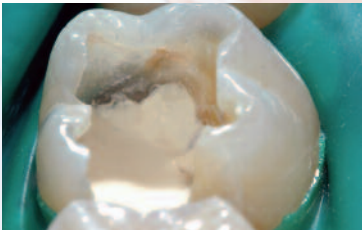
Single point obturation using a tricalcium silicate sealer

Dr. Randall G. Cohen



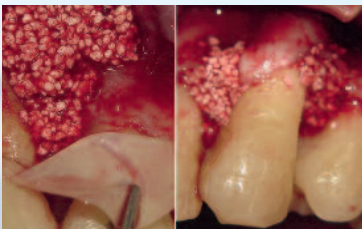Biodentine™ for indirect pulp capping in one session

Dr. Till Dammaschke



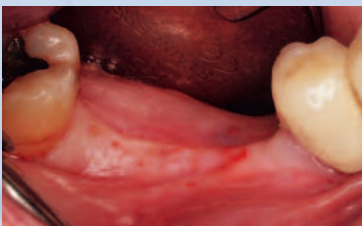Periodontal intraosseous defects and post-extraction compromised socket

Dr. M. E. García Briseño



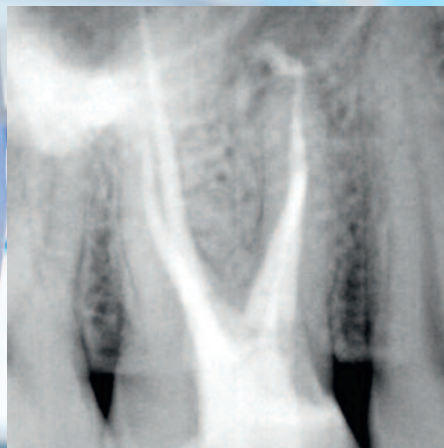Alveolar ridge preservation with alloplastic material

Dr. S. P. Navarro Suárez
Dr. D. Torres Lagares,
Dr. J. L. Gutiérrez Pérez

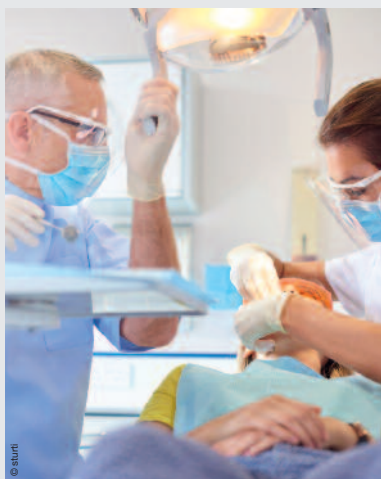

BioRoot™ RCS for retreatment

Dr. Stéphane Simon



Editorial



Since its foundation Septodont has developed, manufactured and distributed a wide range of high quality products for dental professionals.

Septodont recently innovated in the field of endo filling material, dentine care and bone grafting material with the introduction of BioRoot™ RCS, Biodentine™ and R.T.R which are appreciated by clinicians around the globe.

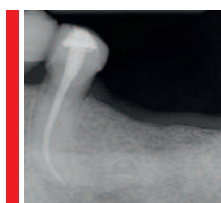
Septodont created the “*Septodont Case Studies Collection*” - a series of case reports - in 2012 to share with you their experience and the benefits of using these innovations in daily practice. Over the past 5 years, authors from more than 15 countries have generously contributed to the success of our magazine that is now distributed on the 5 continents.

Each new issue of the Case Studies Collection is the opportunity to discover new clinical challenges and their treatment solutions.

This 16th issue features one Biodentine™, two R.T.R cases and two new cases report on the most recent Septodont Innovation : BioRoot™ RCS.

- BioRoot™ RCS is the new paradigm for endodontic obturations. Its outstanding sealing properties combined with antimicrobial and bioactive properties allow to get a high seal of the endodontium without having to use complex warm gutta techniques.
- Biodentine™, the first biocompatible and bioactive dentin replacement material. Biodentine™ uniqueness not only lies in its innovative bioactive and “pulp-protective” chemistry, but also in its universal application, both in the crown and in the root.
- R.T.R., an easy-to-use synthetic bone grafting material. In addition to its ability to provide an optimal osteoconductive environment to promote the growth of new dense bone, R.T.R. comes in 3 different presentations to suit all clinical situations.

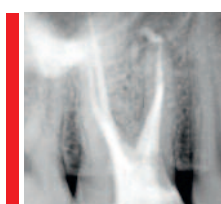
Content



Single point gutta percha obturation using a tricalcium silicate endodontic sealer

Dr. Randall G. Cohen

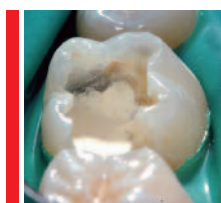
04



Retreatment and BioRoot™ RCS for root canal filling

Prof. Stéphane Simon

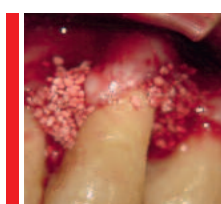09



Indirect pulp capping with Biodentine™ and a definite composite resin restoration in one session

Prof. Dr. Till Dammaschke

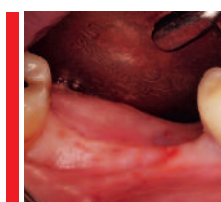15



Periodontal intraosseous defects and post-extraction compromised socket. Treatment with Beta Tricalcium Phosphate

Dr. Mario Ernesto García Briseño

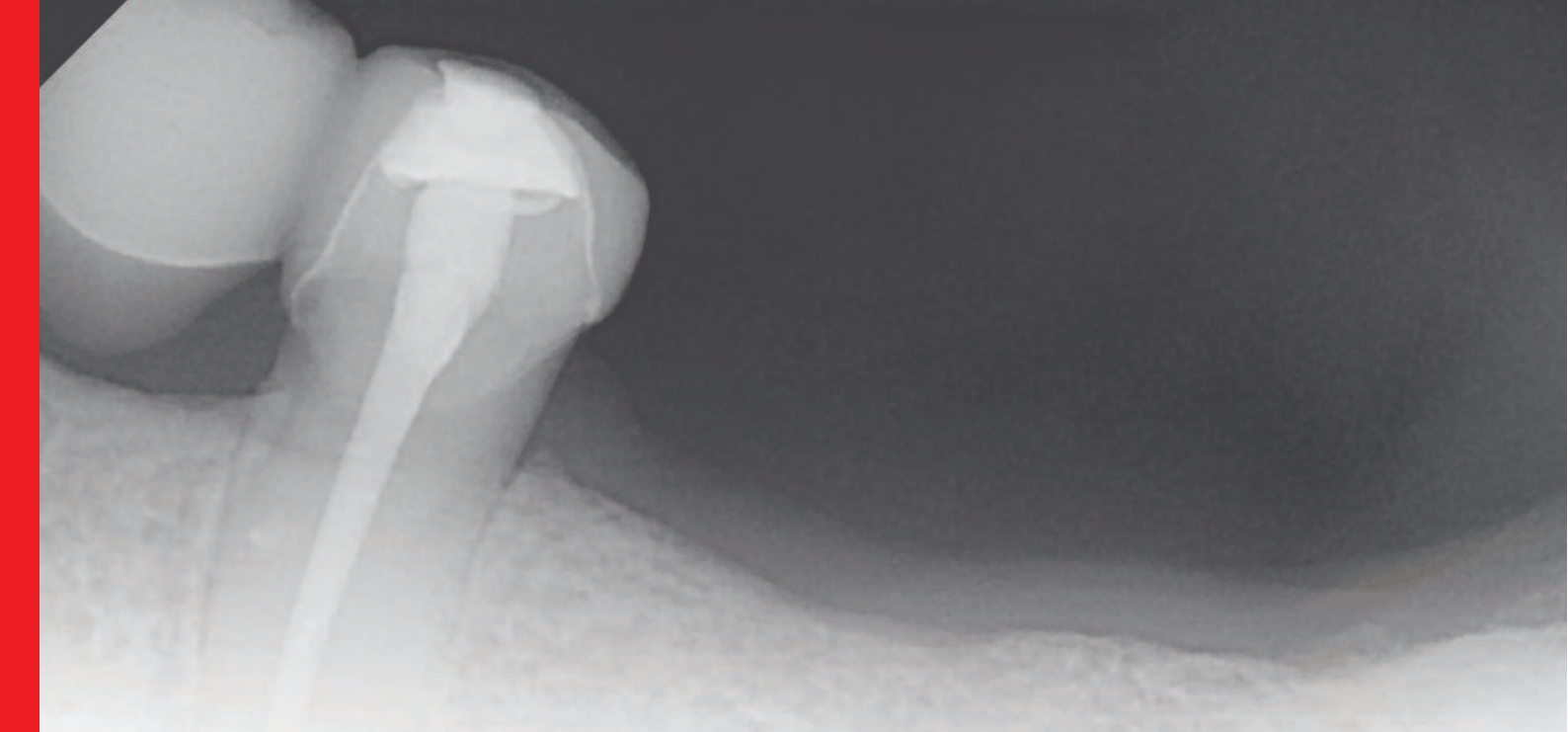
20



Clinical case of alveolar ridge preservation with alloplastic material: Results at 6 months

Dr. S. P. Navarro Suárez, Dr. D. Torres Lagares,
Dr. J. L. Gutiérrez Pérez

25



Single point gutta percha obturation using a tricalcium silicate endodontic sealer

Randall G. Cohen, DDS

Introduction

Lateral condensation and vertical compaction of gutta percha has been in wide use in performing endodontic obturation for decades. Historically this compression of gutta percha has been necessary because the sealers were themselves inadequate. They were hydrophobic, dimensionally unstable, not biocompatible, are susceptible to degradation, and irritating to periodontal tissue if extruded beyond the apex. Accordingly, these condensation techniques (lateral, vertical compaction, and warmed carrier based) were developed in order to minimize the sealer volume. It was acknowledged that more sealer meant more shrinkage, more leakage and more irritation, so techniques were developed to minimize the thickness of the sealer.

In this article, the author reviews the goals for endodontic treatment and the main obturation

methods. Then, a simplified technique will be described that utilizes a single gutta percha point with a new sealer material that overcomes the deficiencies of the older generations of endodontic sealers.

Goals of endodontic therapy

The endodontic triad of biochemical preparation, microbial control and complete obturation of the canal forms the basis for endodontic therapy.¹ The pulp space, chamber and canal must be thoroughly debrided of tissue and properly shaped. This is done by both mechanical and chemical means and when completed, leaves a canal that is free of infection and is ready for obturation.

¹ Cohen S, Hargreaves K. Pathways of the Pulp 9th ed. Mosby, St. Louis, MO, 2006.

A good root canal seal entombs any residual bacteria so that they are deprived of their food supply and are unable to replicate. In addition, the fill material should be antimicrobial so that it does not support further bacterial growth. It is also important to seal off the canal from the oral cavity and from the periapical region so that new bacteria do not cause reinfection.

To accomplish these objectives we use gutta percha, a solid core material that has the desired properties of being non-resorbable, has minimal reactivity with the host tissues, is well tolerated by the body, dissolves in solvents when necessary and is dimensionally stable.

The other component to the endodontic seal is the sealer cement that functions with the gutta percha, the requirements of which are as follows:

1. Easily introduced into the canal
2. Should seal laterally as well as apically
3. Should not shrink after being inserted
4. Should be impervious to moisture
5. Should be bacteriostatic
6. Should be radiopaque
7. Should not stain tooth structure
8. Should not irritate periapical tissues
9. Should be easily sterilized immediately before insertion
10. Should be easily removed from the endodontic system if necessary.²

Current obturation techniques

There are several current techniques for obturating the root canal, all of which employ gutta percha. The first is called Cold Lateral Condensation where the operator has traditionally tapered the canal by way of a “step back” preparation. The master cone is coated with sealer and fitted to length, and then using a spreader, the operator condenses a number of accessory gutta percha points until he or she believes that the remaining

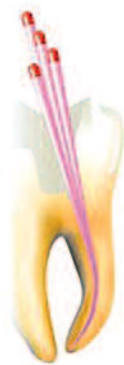

Fig. 1: Lateral condensation.

space between the master cone and the canal walls is fully obliterated.

Another method is Vertical Compaction first described by Schilder³ where a master gutta percha cone is fitted to length, coated with sealer and inserted into the canal. The original method involved heating up a plugger to cherry red then quickly stabbing it into the gutta percha mass leaving behind thermoplastic material that is condensed with a plugger. This method has been shown to generate hydraulic forces that can fill lateral canals as well as the irregularities within the root canal system. The coronal two thirds of the master cone come out when the hot instrument is withdrawn, forming a solid apical plug so that backfilling with softened gutta percha through an extrusion mechanism is controlled. Many advances have occurred concerning this technique, however, it is still difficult to accomplish with many of the problems associated with lateral condensation. One issue is the need to get the hot plugger to within 4 mm from the apex, necessitating the removal of excessive amounts of dentin in the coronal two thirds of the canal.

Other drawbacks include lack of homogeneity, a high proportion of endodontic sealer at the apex, poor adaption to canal walls and apical extrusion of gutta percha.⁴

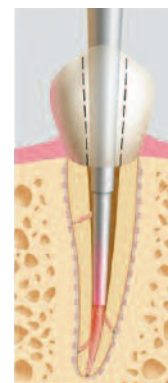


Fig. 2

Of vital importance to the long term survivability of the tooth is the strategic preservation of the coronal dentin of the canal. This translates to making not only as small an endodontic opening into the chamber and the canal as possible, but also in respecting this coronal dentin when creating the final restoration. Unfortunately both of these obturation methods tend to result in canal preparations that take away too much coronal dentin and create a weakness in the structure of the tooth.

² Cohen S, Hargreaves K. Pathways of the Pulp 9th ed. Mosby, St. Louis, MO, 2006.

³ Schilder H. Filling root canals in three dimension, Dent Clin of North Amer 1967;723-44.

⁴ Tasdemir T, Er K, Yildirim T, Buruk K, Çelik D, Cora S, et al. Comparison of the Sealing Ability of Three Different Techniques in Canals Shaped with Two Different Rotary Systems: a Bacterial Leakage Study Oral Surg Oral Med Oral Pathol Oral Radiol Endod. 2009 Sep;108(3):e129-34.

Single cone obturation

Recently there has been an increase in the use of only the master cone, especially in the cases of larger cones with the larger taper sizes that best match the geometry of rotary nickel-titanium systems (NiTi).⁵ This system does not require accessory points, lateral condensation, or warmed vertical compaction. Rather, the canals are shaped with the rotary NiTi files and filled with a master gutta percha cone that matches the last instrument used. This combination of the single cone with the appropriate endodontic sealer results in a uniform mass which prevents failures occurring around multiple cones. This technique takes less time when used with the rotary NiTi instruments, results in less operator fatigue, is easier on the patient and eliminates lateral pressure on the root.

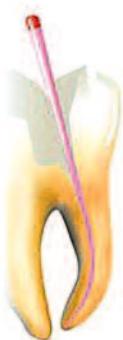

Fig. 3: Single cone technique.

Endodontic instrumentation

The use of NiTi rotary instrumentation sets the case up for a simplified obturation of the canal by enabling the insertion of a snugly fitting a single gutta percha point (corresponding to the last instrument used) to length. When this technique is employed with a bioactive, biocompatible, non-shrinking sealer, the requirements for a successful preparation, disinfection, shaping and seal are met, avoiding the indiscriminate removal of dentin and leading to a higher long term success rate.

The tricalcium silicate endodontic sealer

A tricalcium silicate endodontic sealer, BioRoot™ RCS (Septodont, Inc.) incorporates many improvements over the older materials. Its alkaline pH (imparting antibacterial properties) calcium ion release, and suitable radiopacity and flow characteristics are indeed an advance over earlier formulations. This sealer is dimensionally stable, biocompatible, hydrophilic, stimulates bone growth, and will provide a reliable dentin bond to the radicular dentin.

Clinical Cases

The patient, a 68 year old female came to the office complaining of pain and tenderness in the lower left quadrant. She stated that she was taking Augmentin (antibiotic) as prescribed by her physician. The x-ray revealed a periapical lucency and a diagnosis of periapical abscess was made for tooth #20.

The canal was accessed and shaped to a #30.06 taper. Disinfection was accomplished with a 5% solution of sodium hypochlorite. The canal was flushed with anesthetic solution (Septocaine, Septodont) and followed with an EDTA/chlorhexidine rinse. After another rinse with anesthetic solution the canal was left to soak with 5% sodium hypochlorite. The fit and length of the #30.06 master gutta percha point was verified, then the

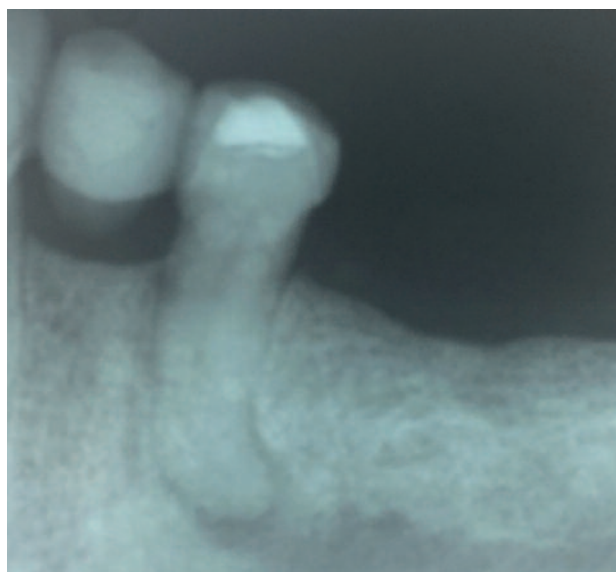


Fig. 1: Pre-Op View; Note periradicular lesion.

⁵ Pereira CA, et. al: Single-Cone Obturation Technique: a literature review. RBSO Oct-Dec 9(4):442-7 2012.

sealer cement (BioRoot™ RCS, Septodont, Inc) was mixed according to manufacturer's directions. The canal was then thoroughly dried using paper points and the master gutta percha point was rolled in the sealer mix and inserted into the canal to length, using the gutta percha to coat the canal walls with BioRoot™ RCS sealer. The master cone was withdrawn, recoated, and inserted to length. The gutta percha was finished at the level of the chamber with a hot plugger, and the seal was further refined using a #2 round bur. (Fig. 1-4).

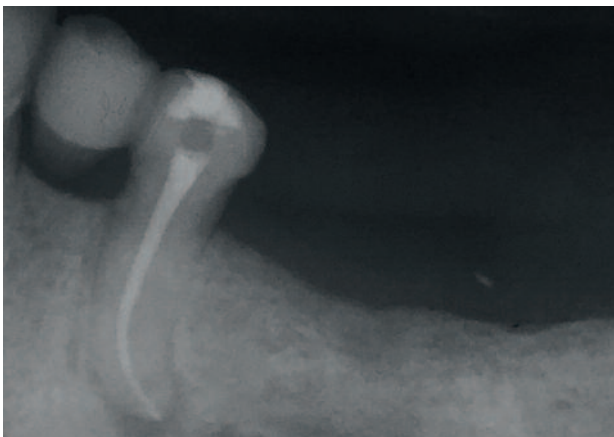


Fig. 3: Master cone coated with BioRoot™ RCS, cemented, and finished with a hot plugger at orifice.

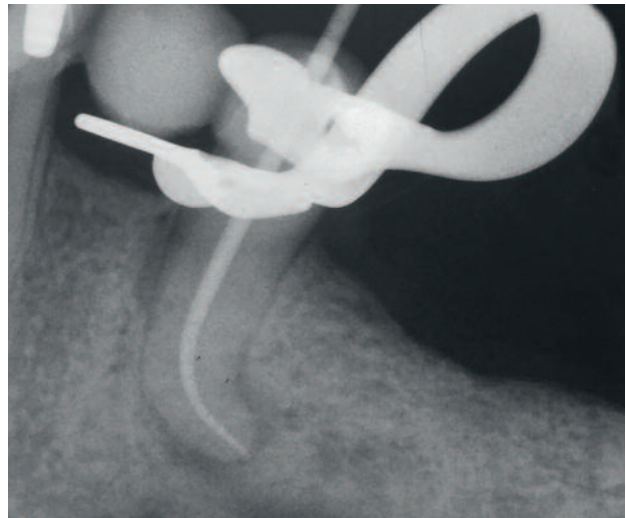


Fig. 2: Canal instrumented, gutta percha master cone fitted to length.

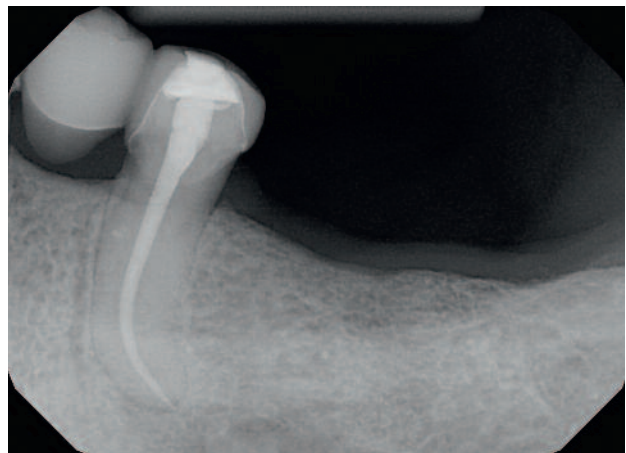


Fig. 4: One year post-op showing complete periapical healing.

Discussion

Successful endodontics requires the complete debridement (mechanically and chemically) of the root canal plus a smooth, tapered shaping so to set the case up for its final seal.

Endodontic sealers have had their shortcomings such as shrinkage, degradation, and tissue irritation. Accordingly, the traditional methods of obturating canals involve compressing the solid core aspect of the fill (gutta percha) so to displace as much of the endodontic sealer as possible. Unfortunately these obturation methods can be time consuming, operator dependent, fatiguing to the patient and to the clinician, and potentially hazardous in that they might cause a fracture of a root due to the pressure exerted. A new method has come into practice which involves the use of a single master gutta percha point in conjunction with a tricalcium silicate

sealer that overcomes the problems that were associated with earlier materials. This tricalcium silicate sealer is antimicrobial, anti-inflammatory, bonds to dentin, and remains dimensionally stable, so that it better meets the stated objectives of root canal sealer materials. According, it is not necessary to use substantial force to compact the gutta percha into the prepared canal, since this sealer will fill voids and prevent bacterial colony formation. Since this sealer neither shrinks nor degrades, micro leakage is prevented apically and coronally. Also, the gutta percha used in this technique slides consistently to length thus making obturation simpler and less likely to result in a root fracture. In addition, not having to create excessive taper strengthens the tooth by preserving the coronal dentin of the root canal preparation.

Conclusion

When the canal is properly cleaned, dried, and shaped, a gutta percha master point that corresponds to the last instrument taken to the apex is coated with BioRoot™ RCS endodontic sealer, inserted to length, and finished with a hot plugger at the level of the canal orifice. This material and technique will meet the objectives

of good obturation by preventing recurrent infection, avoiding procedural accidents, creating a stable long lasting seal, and by preserving the coronal dentin. Taken together, these methods will preserve teeth longer, especially when combined with a rational, tooth-conserving approach to restorative dentistry.



Author:
Randall G. Cohen, DDS

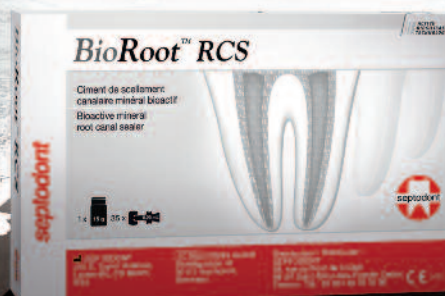Dr. Cohen has been in the practice of general, restorative dentistry with an emphasis on endodontics and surgery since graduating from Temple University in 1982.

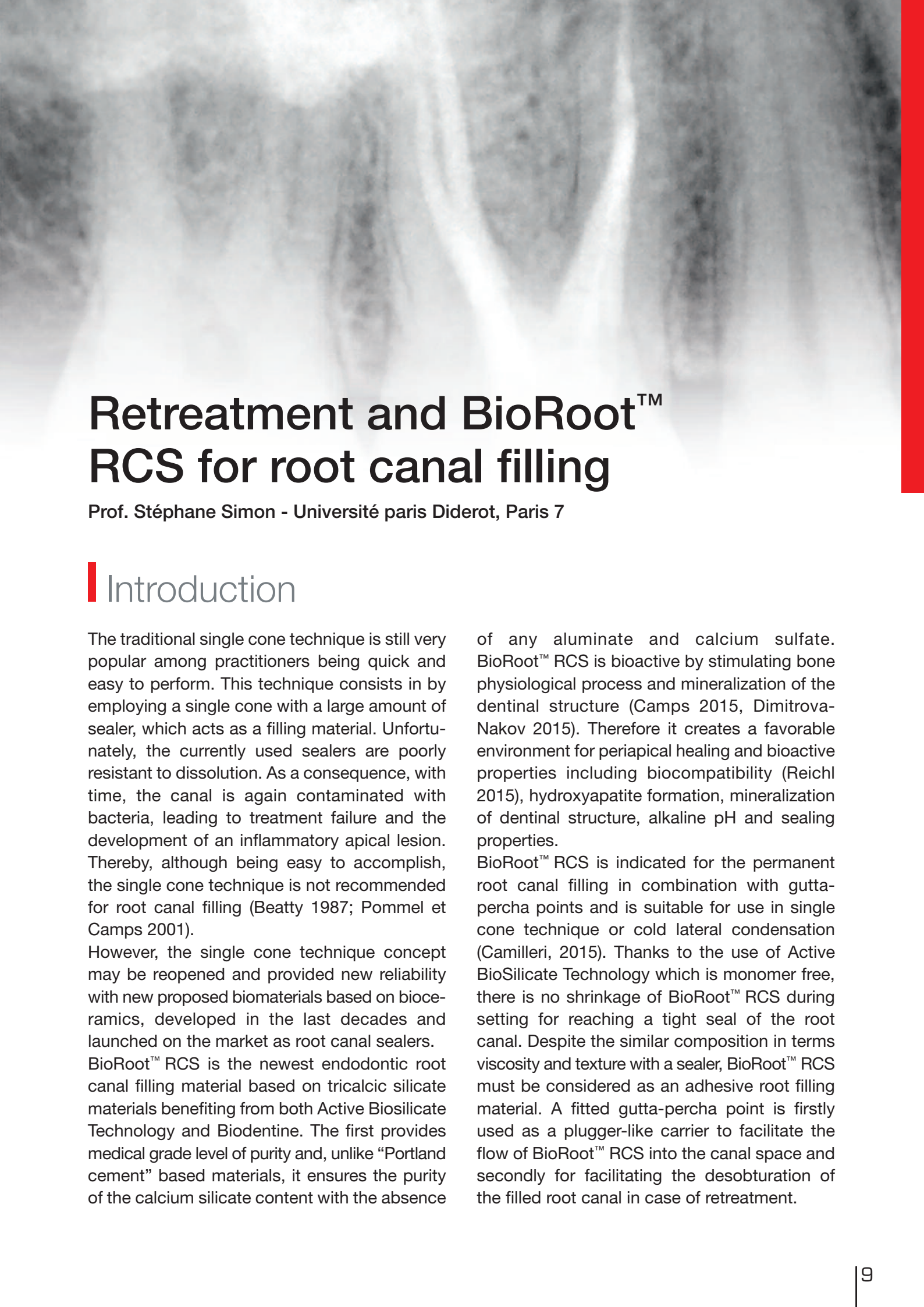
He is an instructor with the Alleman-Deliperi Center for Biomimetic Dentistry, and he has authored many papers and delivered lectures across the US. Dr. Cohen may be reached by writing to his mailbox : rgc7157@gmail.com.

BioRoot™ RCS

Root Canal Sealer

High seal, and much more





Retreatment and BioRoot™ RCS for root canal filling

Prof. Stéphane Simon - Université paris Diderot, Paris 7

Introduction

The traditional single cone technique is still very popular among practitioners being quick and easy to perform. This technique consists in by employing a single cone with a large amount of sealer, which acts as a filling material. Unfortunately, the currently used sealers are poorly resistant to dissolution. As a consequence, with time, the canal is again contaminated with bacteria, leading to treatment failure and the development of an inflammatory apical lesion. Thereby, although being easy to accomplish, the single cone technique is not recommended for root canal filling (Beatty 1987; Pommel et Camps 2001).

However, the single cone technique concept may be reopened and provided new reliability with new proposed biomaterials based on bio-ceramics, developed in the last decades and launched on the market as root canal sealers.

BioRoot™ RCS is the newest endodontic root canal filling material based on tricalcic silicate materials benefiting from both Active Biosilicate Technology and Biodentine. The first provides medical grade level of purity and, unlike “Portland cement” based materials, it ensures the purity of the calcium silicate content with the absence

of any aluminate and calcium sulfate. BioRoot™ RCS is bioactive by stimulating bone physiological process and mineralization of the dentinal structure (Camps 2015, Dimitrova-Nakov 2015). Therefore it creates a favorable environment for periapical healing and bioactive properties including biocompatibility (Reichl 2015), hydroxyapatite formation, mineralization of dentinal structure, alkaline pH and sealing properties.

BioRoot™ RCS is indicated for the permanent root canal filling in combination with gutta-percha points and is suitable for use in single cone technique or cold lateral condensation (Camilleri, 2015). Thanks to the use of Active BioSilicate Technology which is monomer free, there is no shrinkage of BioRoot™ RCS during setting for reaching a tight seal of the root canal. Despite the similar composition in terms viscosity and texture with a sealer, BioRoot™ RCS must be considered as an adhesive root filling material. A fitted gutta-percha point is firstly used as a plugger-like carrier to facilitate the flow of BioRoot™ RCS into the canal space and secondly for facilitating the desobturation of the filled root canal in case of retreatment.

Description of the technique

From an operational point of view, the procedure is very similar to the single cone technique. However, few indispensable differences justify the reliability of BioRoot™ RCS with such a technique. Notably, the single cone technique seals a cone alone. Instead, here the cone is

employed as a carrier, which is left in place to allow the material removal in case of retreatment. Indeed, it must not be considered as the core of the filling. The obturation is made by BioRoot™ RCS itself.

Case report 1

A pulp necrosis was diagnosed on tooth #16 of a 35 years old female patient associated with a chronic periapical disease (*Fig. 1*). Patient was suffering of chronic sinusitis for over than 2 years and received unseccessful medical treatments.

- After having shaped the root canal and obtained an appropriate tapered preparation, the canal was disinfected with a 3% sodium hypochlorite solution activated with mechanical agitation (Irrigatys, Itena, France). A final rinse with 17% EDTA and a final flush with sodium hypochlorite were completed before fitting the gutta percha cones.
- Canals were dried with paper points.
- BioRoot™ RCS was mixed, following manufacturer recommendations.
- BioRoot™ RCS was injected into the root canals with a spiral used with at low sped of rotation (800 r/min). Each gutta percha point was

poured into the mixed material to largely cover the surface of the cone. Afterward, it was gently inserted into the root canal space until reaching the working length.

- The cone was cut at the entrance of the root canal with a heat carrier, and a slight plug was created with a hand plugger.
- The second and the third canal were filled in the same way (*Fig 2*).
- The patient was refered to the general practitioner who restored the tooth with a bonded overlay.
- Patient was recalled at 6 and 12 months after treatement. She didn't suffer of sinusitis anymore and the tooth is asymptomatic. The 12 months recall let show a complete healing of the periapical lesion (*Fig 3*). Thereby, the treatment maybe considered as successful.

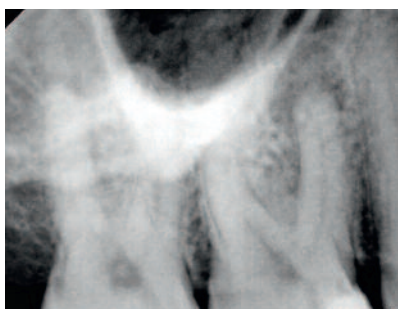

Fig. 1: Pre-operative X ray of tooth #16 of a 35 years old female patient.

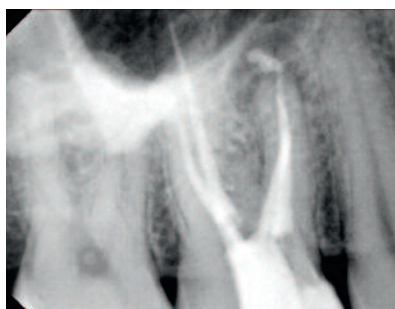

Fig. 2: Post-operative X ray after completion of endodontic treatment.

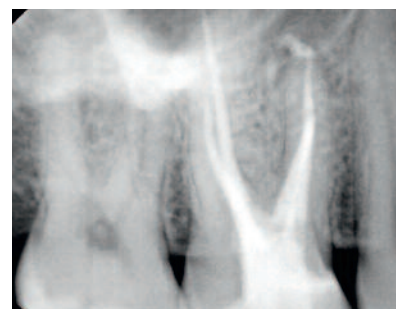

Fig. 3: 6 months post-operative recall.

Case report 2

A 32 years old female was referred to our endodontic department by her general practitioner for treatment on tooth #47 (*Fig. 4*). The patient reports a long painful dental history on this tooth. Root canal treatment had been initiated 6 months before, and several practitioners tried to complete the root canal treatment, unsuccessfully. The patient complained about severe pain and sensation of numbness and loss of sensitivity of the mandible each time the access cavity was closed with a temporary filling.

An intra osseous injection (one cartridge articaine + 1/100000 epinefrin (Septodont, France) was completed and root canals were shaped and disinfected with a large volume of sodium Hypochlorite activated with Irrigatys (Itena, France). The canals were dried, and temporary filled with a calcium hydroxide based medication. Access cavity was filled with a temporary filling and the crown was drilled for occlusal reduction.

At the second visit, the root canal treatment was completed. Because the proximity of the inferior dental nerve, everything was done to avoid any extrusion of dental material. Because its excellent bio-tolerance and non toxicity, BioRoot™ RCS was considered as the material of choice for filling the root canals.

Root canals were rinsed again with Sodium Hypochlorite and 17%EDTA, and then dried. BioRoot™ RCS was placed inside each canal with a spiral (800 r/min) and gutta percha points were poured into the material and gently paced inside the canals up to the working length (*Fig. 5*).

The coronal restoration was completed on a third visit with a CAD/CAM bonded overlay (*Fig 6, 7 and 8*).

The patient never complained on any pain, neither discomfort. The 6 months recall X Ray confirm the complete healing of the apical lesions (*Fig. 9*).

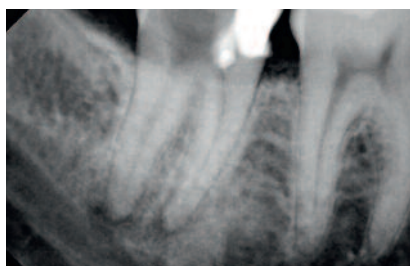


Fig. 4: Pre-operative X ray of tooth #47 of a 32 years old female patient..

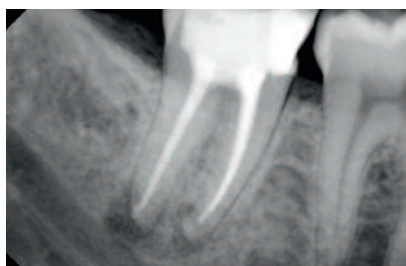


Fig. 5: Post-operative X ray after completion of endodontic treatment.

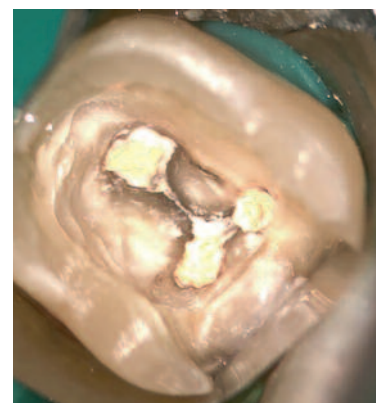


Fig. 6: Occlusal view of the access cavity before coronal restoration.

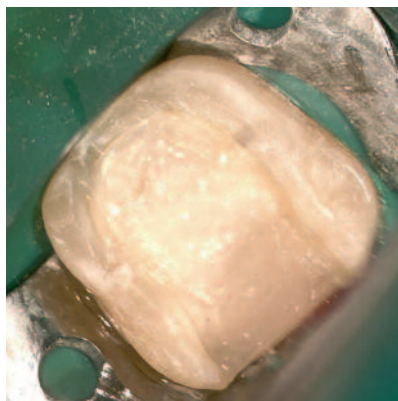


Fig. 7: Pre-prosthetic coronal restoration with a bonded composite resin.

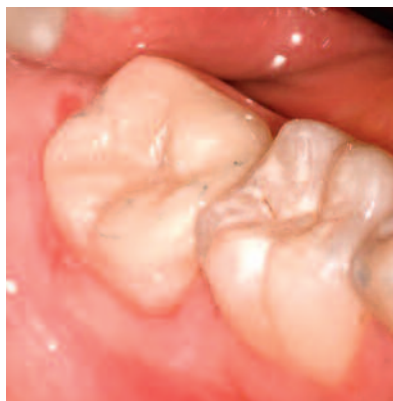

Fig. 8: CAD/CAM overlay for coronal restoration.

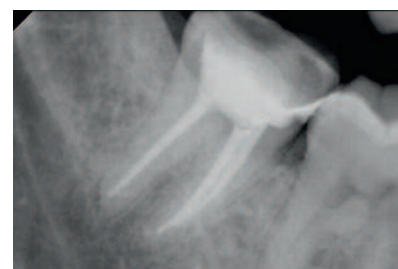

Fig. 9: 6 months post-operative recall.

Case report 3

A 31 years old female patient was referred for a root canal retreatment on tooth #46 (*Fig. 10*). This tooth had already been retreated twice recently, but the patient still complained about pain and abscesses since the tooth had been restored with a post placed into the distal root. Because the post was not visible on the pre-operative Xray, it was assumed that it might be a fiber post. The shape of the inter-radicular lesion let us suspect a zipping perforation into the interradicular area.

Root canal retreatment was completed in one visit. The fiber post of distal root and root canal filling material were removed with rotary and manual instruments. The four root canals were then reshaped and disinfected with 3% sodium hypochlorite with mechanical activation and 17% EDTA. During the retreatment process, an inter-radicular perforation (mesial side of the Disto-lingual root canal) was highlighted (*Fig. 11*). In the past, this type of disease would have completed into two steps. First step for filling the root canal up to the level of the perforation, with precaution to avoid any extrusion of materials through the perforation, and the second step for filling the last third of the canal with a silicate based material such as Biodentine (Septodont). Because BioRoot™ RCS is a Tricalcium silicate

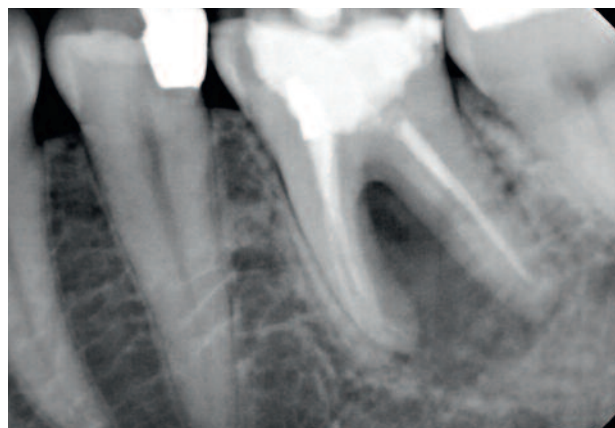


Fig. 10: Pre-operative X ray of tooth #36 of a 31 years old female patient.

based filling material, it was decided to combine the two steps in one by filling the canals and the perforation in the same time.

Like for the two previous cases, root canals were dried with paper points, BioRoot™ RCS was injected into the canals with a spiral used at low speed (800r/min) and gutta fitted gutta percha points were inserted into each canal up to the working length (*Fig. 12*). A small extrusion of material is visible on the post operative X-Ray, as a confirmation of perforation closure (*Fig. 13*). Tooth was restored with a bonded overlay (*Fig. 14,15*) and the patient was recalled at 6 months post operative (*Fig. 16*).

The tooth is asymptomatic and fonctionnal ; the peridon tal probing is normal, and the 6 months recall X-ray confirm the bone healing of the inter-radicular lesion.

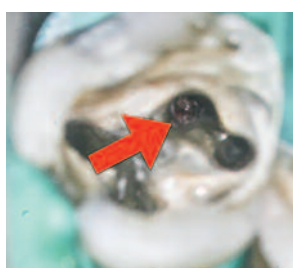

Fig. 11: Highlight of the stripping perforation on the mesial side of the distal root canal.

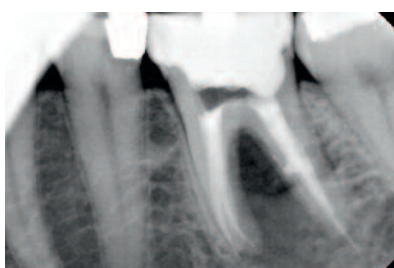


Fig. 12: Post-operative X ray after completion of endodontic treatment.

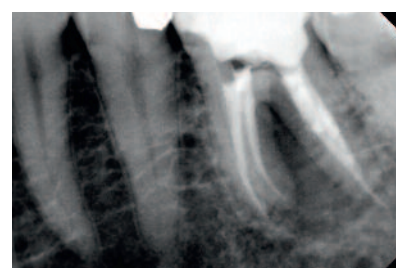

Fig. 13: Decentered post operative X-Ray showing the slight extrusion of material in the inter-radicular area.

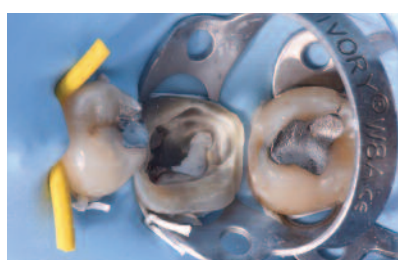


Fig. 14: Clinical view of the acces cavity before restoration

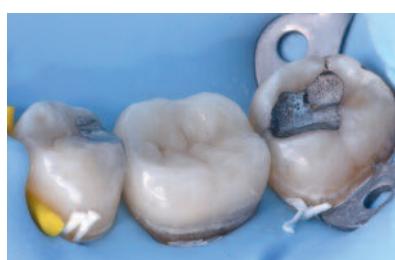

Fig. 15: Final prosthetic restoration with a bonded crown (Dr Alexandre Sarfati - Paris).

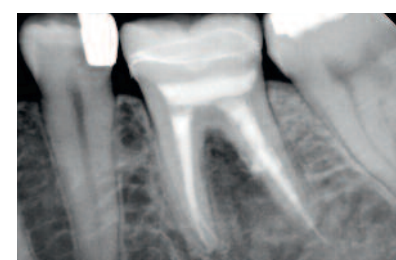

Fig. 16: 6 months post-operative recall.

These cases are used to illustrate some specific situation in which we used BioRoot™ RCS because its valuable properties. These are three of a large number of cases we have completed for the last 18 months. Before the launch of this product, 22 clinical cases were completed in the frame of a randomized clinical trial comparing the succes of an endodontic treatment using

warm vertical compaction of Gutta percha versus the above described BioRoot™ RCS. The RCT registration number is NCT01728532 and the full protocol is available on <https://clinicaltrials.gov> The results are, at the time we are writing these lines, under analysis and very encouraging, which it allows us to consider this technique as reliable enough to be described here.

Conclusion

Endodontics is continously under evolution. In the last 20 years, instrumentation research and development have been very active. Currently, disinfection and irrigation procedures are the two most focused aspects of endodontic research. The shaping procedures and root canal disinfection have considerably been simplified. Thereby, every practitioner interested in endodontics is now able to complete any easy/middle difficulty root canal treatment with reproducible results without any issue. Obturation, the final step of the proce-

cedure, is usually the most difficult and time consuming operation. However, with this new approach of root canal filling, this milestone may be overpassed. Considering the fluidity of BioRoot™ RCS as a filler and not only as a sealer, this represents a true paradigm shift. The preliminary results of the randomized clinical trial are very encouraging. More clinical investigations will be necessary in the future to confirm this new vision of a simpler root canal obturation.



Authors: Stéphane SIMON

Stéphane SIMON has been qualified as Doctor in Dental Surgery in 1994 at the University of Reims. He completed in 2009 his PhD in Pulp Biology in the frame of a co-supervised Thesis between the Paris Diderot University (Paris 7) and the University of Birmingham (UK). In february 2016, he passed his "*Habilitation à diriger des recherches*" (Paris Diderot University). He used to work in a private

practice limited into endodontics for 18 years before joining the staff of Paris Diderot University for a full time academic career.


To date he is full time teacher/researcher/Hospital clinician, and has been appointed as Professor in Conservative Dentistry and Endodontics in 2016. He is the director of the Postgraduate Endodontic Program at Paris Diderot University (3 years full time program) and is highly involved in teaching and research (Clinical and basic research). His time is 50% devoted to the clinical practice (Groupe Hospitalier Pitié Salpêtrière) and 50% to Basic Science and clinical research about Tissue engineering and dental Pulp healing/regeneration. He works as a Researcher in Paris Diderot University (Laboratory INSERM UMR1138) and as Associate Researcher at University of Birmingham.

Today, his main interest is about Tissue engineering, cell and molecular Biology of pulp tissue (Basic science and clinical practice), and modern techniques for teaching (E learning, flipped classroom, MOOCs, etc.)

He authored 25 scientific per reviewed papers, more than 80 clinical publications (French and international), 6 french books and 6 book chapters.

References

- Angerame D, De Biasi M, Pecci R, Bedini R, Tommasin E, Marigo L, Somma F. Analysis of single point and continuous wave of condensation root filling techniques by micro-computed tomography. *Ann Ist Super Sanita*. 2012;48(1):35-41.
- Best SM, Porter AE, Thian ES, Huang J. Bioceramics: Past, present and for the future, *Journal of the European Ceramic Society* 2008; 28:1319–1327.
- Beatty RG. The effect of standard or serial preparation on single cone obturation. *Int Endod J* 1987;20:276 – 81.
- Camps et al. Bioactivity of a calcium silicate-based endodontic cement (BioRoot™ RCS): interactions with human periodontal ligament cells in vitro, *J Endod* 2015 Sept; 41 (9): 1469–73
- Dimitrova-Nakov et al., Bioactivity of Bioroot™ RCS, a root canal sealer, via A4 mouse pulpal stem cells in vitro. 2015 *Dental Materials* : available online.
- Dubok VA. Bioceramics yesterday, today, tomorrow. *Powder Metallurgy and Metal Ceramics* 2000; 39(7-8)
- Koch K, Brave D. Bioceramic technology - the game changer in endodontics. *Endodontic Practice US*.2009;12:7–11.
- Koch KA, Brave GD, Nasseh AA. Bioceramic technology: closing the endo-restorative circle, part 2. *Dentistry today*. 2010; 29(3):98-100.
- vKoch KA, Brave D. Endosequence: melding endodontics with restorative dentistry, part 3. *Dent Today*. 2009, 28(3):88-90.
- Pommel L, Camps J. In vitro apical leakage of system B compared with other filling techniques. *J Endod*. 2001 Jul;27(7):449-51.
- Ray HA, Trope M. Periapical status of endodontically treated teeth in relation to the technical quality of the root filling and the coronal restoration. *Int Endod J*. 1995 Jan;28(1):12-8.
- Reichl FX1,2, Rothmund L1,2, Shehata M1,2, Högg C1,2 DNA double-strand breaks caused by new and contemporary endodontic sealers. *Int Endod J*. 2015 Nov 17.
- Schäfer E1, Köster M, Bürklein S. Percentage of gutta-percha-filled areas in canals instrumented with nickel-titanium systems and obturated with matching single cones. *J Endod*. 2013 Jul;39(7):924-8.
- Siqueira JF, Arujo MCP, Garcia PF, Fraga RC, Saboia Dantas CJ. Histologic evaluation of the effectiveness of five instrumentation techniques for cleaning at the apical third of root canals. *J Endod* 1997; 23:499-502.
- Somma F1, Cretella G, Carotenuto M, Pecci R, Bedini R, De Biasi M, Angerame D. Quality of thermoplasticized and single point root fillings assessed by micro-computed tomography. *Int Endod J*. 2011 Apr;44(4):362-9.
- Trope M, Debelian G. Bioceramic Technology in Endodontics. *Inside dentistry*. 2014 nov: 53-57
- Tyagi S, Mishra P, Tyagi P. Evolution of root canal sealers: An insight story. *European journal of dentistry*. 2013; 2(3):199.
- Xuereb et al., 2014 In Situ Assessment of the Setting of Tricalcium Silicate–based Sealers Using a Dentin Pressure Model, *J Endod*. 2015 Jan;41(1):111-24.
- Yang Q, Lu D. Premixed biological hydraulic cement paste composition and using the same. Patent application 2008029909, December 4, 2008.
- Zhang H, Shen Y, Ruse ND, Haapasalo M. Antibacterial activity of endodontic sealers by modified direct contact test against *Enterococcus Faecalis*. *Journal of endodontics* 2009;35(7):1051-5.
- Zhang W, Li Z, Peng B. Effects of iRoot SP on mineralization-related genes expression in MG63 cells. *Journal of endodontics*. 2010; 36(12):1978-82.
- Zhang W, Li Z, Peng B. Ex vivo cytotoxicity of a new calcium silicate based canal filling material. *International endodontic journal*. 2010;42(9):769-74.

A close-up photograph of a dental restoration on a tooth model. The restoration is a white, translucent composite resin filling a cavity. The surrounding tooth structure is a light yellowish-brown color. The background is a soft, out-of-focus white.

Indirect pulp capping with Biodentine™ and a definite composite resin restoration in one session

Prof. Dr. Till Dammaschke

Introduction

Indirect capping of the dental pulp is defined as medication of a thin layer of dentine that remains above the vital pulp after cavity preparation (Schäfer et al. 2000). Clinically, this situation usually arises during the excavation of a profound caries. But also after a dental trauma, the pulp of a caries-free tooth may be capped indirectly (Staehle and Pioch 1988).

Because there is only a minimal dentine layer remaining above the vital pulp tissue, there is the danger that an irreversible inflammation of the pulp may occur via dentine tubules: on the one hand, by microorganisms which have already penetrated into the tissue or on the other hand by cytotoxic components of the restoration materials. With a pulp capping material, the caries-free dentine should be sealed and disinfected and the pulp tissue should be stimulated to form tertiary dentine (Ricucci et al. 2014). The formation of tertiary dentine is also referred to as a reaction dentine. Reaction dentine is defined as a dentine formed by surviving post-mitotic primary odontoblasts (Smith 2012).

The indirect pulp capping thus serves to protect vital tissue, especially after caries removal. If

there is already an existing reversible pulpitis, the preconditions for pulp healing should be created by indirect pulp capping (Damaschke 2016).

Maintaining pulp vitality and thus a successful indirect capping presupposes a curable pulp, thus the pulp tissue should be healthy or only reversibly damaged. In the case of teeth which have profound periodontal defects or have already been repeatedly extensively restored, regenerative capacity of the pulp is reduced (Duda and Dammaschke 2009).

For the success of an indirect capping is also important that aseptic operation can be ensured throughout the treatment. Since the presence of microorganisms in the area of the pulp capping is inevitably associated with a considerable reduction in the prognosis (Kakehashi et al. 1965, Ricucci and Siqueira 2013), an indirect capping should be carried out whenever possible under rubber dam (Damaschke 2016).

Therefore, the removal of the irritation factors (caries), the control of the infection and the biocompatibility of the pulp capping material are important prerequisites for a successful vital maintenance (Seltzer and Bender 1984).

Clinical Case

A 23-year-old male patient came for a routine check-up. Diagnostic assessment as well as a radiograph showed signs of a deep carious lesion occlusal on tooth 36 (*Fig. 1*). The patient was informed about the need of having the carious lesion treated. The tooth was tested positive on CO₂ snow sensitivity and negative on percussion. After thorough information of the patient, an anesthetic (Septanest, 1.7 ml; Septodont, St. Maur-des-Fossés, France) was injected for terminal anesthesia and a rubber dam was put in place. Following the cavity preparation occlusal and distal (*Fig. 2*) the carious dentine was excavated. To avoid unnecessary removal of unaffected dentine and iatrogenic pulp exposure, the excavation of the profound caries on tooth 36 was performed with a self-

limiting polymer round bud bur (Polybur P1; Komet, Lemgo, Germany) (*Fig. 3*). After cavity toilet with NaOCl (3 %) for clearing and disinfecting, Biodentine™ (Septodont, St. Maur-des-Fossés, France) was chosen for indirect pulp capping. Mixed as recommended by the manufacturer, Biodentine was applied onto the cavity floor with cement pluggers as (sub)base for indirect capping and to protect the underlying pulp tissue (*Fig. 4*). After mixing, Biodentine™ needs at least 15 min to set before the treatment could be continued. Then, the entire cavity (including the Biodentine™ surface) was treated with a self-etching dentine adhesive (Optibond XTR; Kerr, Orange, CA, USA). Finally, the cavity was restored with a composite filling material (Grandio; VOCO, Cuxhaven, Germany) (*Fig. 5*).

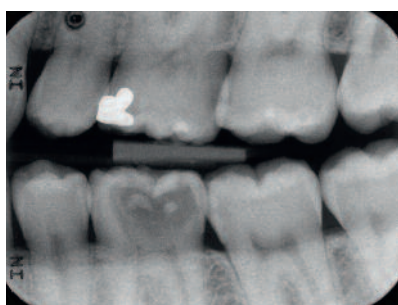


Fig. 1: Bitewing Radiograph revealed signs of a deep carious lesion occlusal on tooth 36 of a 23-years-old male patient.

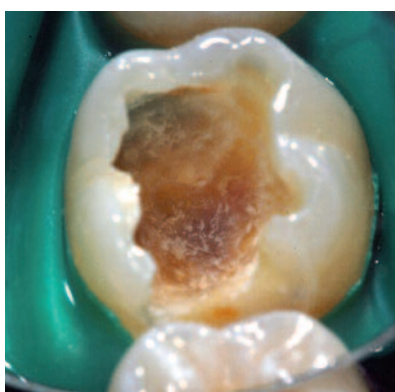


Fig. 2: Cavity preparation under rubber dam and incomplete caries excavation on tooth 36.

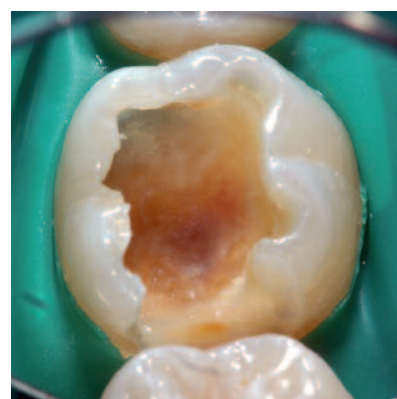


Fig. 3: To avoid unnecessary removal of unaffected dentine and iatrogenic pulp exposure, the excavation of the profound caries on tooth 36 was performed with a self-limiting polymer round bud bur (Polybur P1; Komet, Lemgo, Germany).

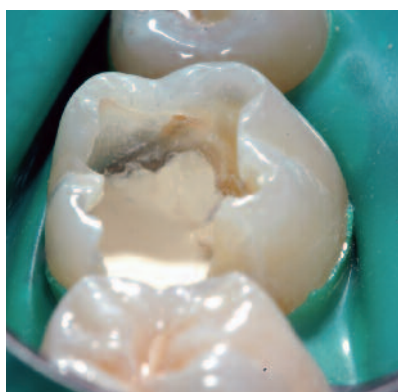


Fig. 4: For indirect pulp capping Biodentine (Septodont; St. Maur-des-Fossés, France) was applied to the cavity as a subbase with cement pluggers. Biodentine was used as pulp protection material (maintaining pulp vitality) and base at the same time. Biodentine™ should not be prepared with rotating instruments and should not come into contact with water during setting time.

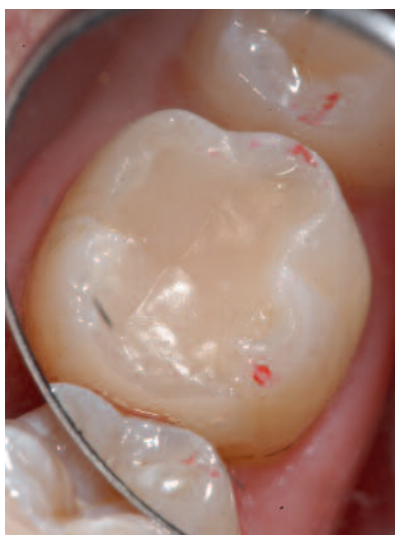

Fig. 5: After allowing 15 minutes for Biodentine™ to set, the cavity was directly restored with composite (Grandio, VOCO, Cuxhaven, Germany) at the same appointment. For this, the entire cavity (including the Biodentine surface) was treated with a self-etching dentine adhesive (Optibond XTR; Kerr, Orange, CA, USA). The use of self-etching dentine adhesives is favorable to avoid an etching with phosphoric acid and rinsing with water of the Biodentine™. There is no need to use e.g. glass ionomer cement under the composite restoration.

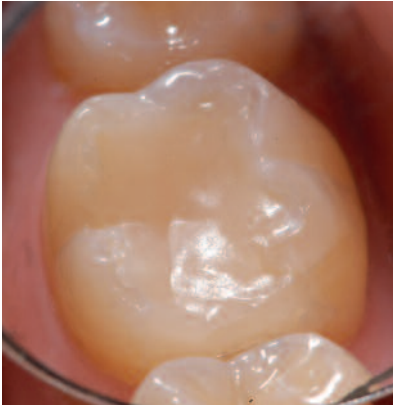

Fig. 6: Composite (occlusal-distal) filling 3.5 years after restoration of tooth 36. The patient reported about no discomfort on tooth 36 at any time after indirect pulp capping, e.g. upon contact with cold food, drinks and air, or other subjective symptoms.

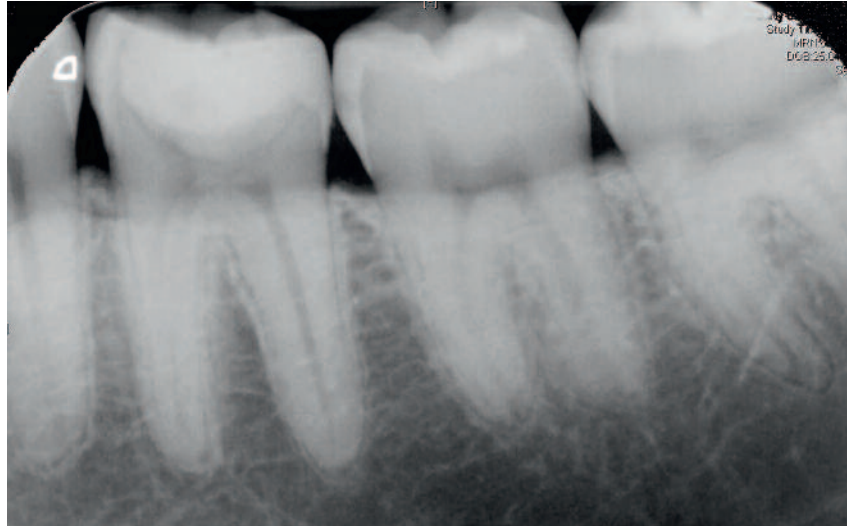


Fig. 7: The dental film recorded 3.5 years after indirect capping does not show any pathological findings apical of tooth 36. (Caries mesial on tooth 37).

At the follow-up visit 3.5 years after indirect pulp capping tooth 36 was clinically normal (**Fig. 6**) and again tested positive for sensitivity and negative for percussion. The dental film recorded at that time did not show any patholo-

gical findings apically (**Fig. 7**). The patient reported about no discomfort on tooth 36 at any time after pulp capping, e.g. upon contact with cold food, drinks and air, or other subjective symptoms.

Discussion

The primary aim of a pulp capping material is to induce a specific hard tissue formation by pulp cells that seal the exposure site and ultimately contribute to continued pulp vitality (Schröder 1985). Recently, it was shown that clinically and histologically Biodentine™ is significantly superior to Dycal even in direct pulp capping (Jalan et al. 2017). Used for pulp capping, this cement offers some benefits compared to calcium hydroxide: It is mechanically stronger, less soluble and produces tighter seals (Pradelle-Plasse et al. 2009). This qualifies it for avoiding three major drawbacks of calcium hydroxide, i.e. material resorption, mechanical instability and the resultant failure of preventing microleakage (Dammaschke et al. 2014). Thus, in the present case report Biodentine was used for indirect pulp capping: as pulp protection material (maintaining pulp vitality) and base at the same time. Then, the cavity was restored with a composite resin during the same appointment. This treat-

ment option offers several advantages: for successful pulp capping it is important to seal the cavity against bacterial invasion in a one-stage procedure (Duda and Dammaschke 2009, Dammaschke et al. 2010).

When opting for this one visit approach it is, however, important to wait for Biodentine™ to set (minimum 15 minutes after mixing) before proceeding with the restorative treatment. During the setting time the cement should not be prepared with rotating instruments and should not come into contact with water.

To bypass the long setting time of calcium silicate cements, it has been suggested to use light-curing resins as lining materials. Recently, it was shown that already 3 min after mixing of Biodentine™ shear bond strength of light-curable composite resins on Biodentine™ were similar to those after 15 min and 2 d. Thus, the final adhesive composite resins restoration can be placed over Biodentine™ shortly after mixing

(Schmidt et al. 2017). Self-etching dentine adhesives should be preferred for this procedure to avoid an etching with phosphoric acid and rinsing with water of the Biodentine™ surface. There is no need to use e.g. glass ionomer cement under the composite restoration. After setting, the mechanical properties like compressive strength, flexural strength, E-module and Vickers hardness of Biodentine™ are comparable to human dentine (Pradell-Plasse et al. 2009, Camilleri 2013, Kaup et al. 2015b). Furthermore, the shear bond strength of Biodentine™ to human dentine is comparable to glass ionomer cements (Kaup et al. 2015a). The excavation of the profound caries was performed with a self-limiting polymer round

bud bur (Polybur P1; Komet, Lemgo, Germany). This was done to avoid unnecessary removal of unaffected dentine and iatrogenic pulp exposure on tooth 36. The hardness of the polymer is less than healthy and higher than cariously altered dentine. As soon as the blades hit healthy dentine, they become flat and thus the disposable instrument becomes unusable. Thus, no healthy dentine is removed. But the dentine surface does not look longer as smooth and hard as it will be after excavation with a stainless steel bud bur (*Fig. 3*). The remaining only partial dematerialized dentine causes fewer x-rays to be absorbed. This thin line of partial dematerialized dentine may be misinterpreted as secondary caries in radiographs (*Fig. 7*).



Author:

Till Dammaschke, Prof. Dr. med. dent.

Till Dammaschke started studying sociology, political science and history at the University of Göttingen (Germany) in 1986. From 1987 to 1993, he studied dentistry at the University of Göttingen (Germany). Till Dammaschke is working at the Department of Operative Dentistry at the University of Münster (Germany) since 1994. In 1996, he completed his doctoral thesis at the University of Göttingen (Germany).

In 2012, he was appointed as Professor. Since 2015 Till Dammaschke is head of the section "Cariology and Paediatric Dentistry" in the Department of Periodontology and Operative Dentistry in Münster (Germany).

Till Dammaschke has nearly 100 national and international publications in scientific dental journals (more than 30 in "Web of Science", e.g. Journal of Endodontics, International Endodontic Journal, Journal of Dentistry, Dental Materials, Clinical Oral Investigations, Quintessence International, Journal of Adhesive Dentistry), is co-author in books (e.g. Torabinejad M (ed.) Mineral Trioxide Aggregate: Properties and Clinical Applications.), and peer reviewer of more than 30 national and international dental scientific journals.

References

- Camilleri J. Investigation of Biodentine as dentine replacement material. J Dent 2013; 41: 600-610.
- Dammaschke T, Camp JH, Bogen G. MTA in Vital Pulp Therapy. In: Torabinejad M (ed.) Mineral Trioxide Aggregate – Properties and Clinical Applications. Wiley Blackwell, Ames, 2014, pp. 71-110.
- Dammaschke T, Leidinger J, Schäfer E. Long-term evaluation of direct pulp capping-treatment outcomes over an average period of 6.1 years. Clin Oral Investig 2010; 14: 559-567.
- Dammaschke T. Die indirekte Überkappung der Pulpa. Quintessenz 2016; 67: 1309-1316.
- Duda S, Dammaschke T. Die direkte Überkappung. Voraussetzungen für klinische Behandlungserfolge. Endodontie 2009; 18: 21-31.


- Jalan AL, Warhadpande MM, Dakshindas DM. A comparison of human dental pulp response to calcium hydroxide and Biodentine as direct pulp-capping agents. J Conserv Dent 2017; 20: 129-133.
- Takehashi S, Stanley H, Fitzgerald R. The effects of surgical exposures of dental pulps in germ-free and conventional laboratory rats. Oral Surg Oral Med Oral Pathol 1965; 20: 340-349.
- Kaup M, Dammann CH, Schäfer E, Dammaschke T. Shear bond strength of Biodentine, ProRoot MTA, glass ionomer cement and composite resin on human dentine ex vivo. Head Face Med 2015a, 11: 14. doi: 10.1186/s13005-015-0071-z.
- Kaup M, Schäfer E, Dammaschke T. An in vitro study of different material properties of Biodentine compared to ProRoot MTA. Head Face Med 2015b; 11: 16. doi: 10.1186/s13005-015-0074-9.
- Pradelle-Plasse N, Tran X-V, Colon P. Physico-chemical properties. In: Goldberg M, (ed). Biocompatibility or cytotoxic effects of dental composites. Coxmoor, Oxford, 2009, pp. 184-194.
- Ricucci D, Loghin S, Lin LM, Spångberg LS, Tay FR. Is hard tissue formation in the dental pulp after the death of the primary odontoblasts a regenerative or a reparative process? J Dent 2014; 42: 1156-1170.
- Ricucci D, Siqueira JF Jr. Vital pulp therapy. In: Ricucci D, Siqueira JF Jr. (eds). Endodontology – an integrated biological and clinical view. Quintessence, London, 2013, pp. 67-106.
- Schäfer E, Hickel R, Geurtsen W et al. Offizielles Endodontologisches Lexikon – mit einem Anhang für Materialien und Instrumente – der Deutschen Gesellschaft für Zahnerhaltung. Endodontie 2000; 9: 129-160.
- Schmidt A, Schäfer E, Dammaschke T. Shear bond strength of lining materials to calcium silicate cements at different time intervals. J Adhes Dent 2017; 19: 129-135.
- Schröder U. Evaluation of healing following experimental pulpotomy of intact human teeth and capping with calcium hydroxide. Odontol Revy 1972; 23: 329-340.
- Seltzer S, Bender IB. Pulp capping and pulpotomy. In: Seltzer S, Bender IB. The dental pulp. 3. ed. J. B. Lippincott, Philadelphia, 1984, pp. 281-302.
- Smith AJ. Formation and repair of dentin in the adult. In: Hargreaves KM, Goodis HE, Tay FR (eds.) Seltzer and Bender's Dental Pulp. 2nd ed. Quintessence Publishing, Chicago, 2012, pp. 27-46.
- Staehle HJ, Pioch T. Zur alkalisierenden Wirkung von kalziumhaltigen Präparaten. Dtsch Zahnärztl Z 1988; 43: 308-312.

Download the complete series

Septodont Case Studies Collection

www.septodont.com





Periodontal intraosseous defects and post-extraction compromised socket. Treatment with Beta Tricalcium phosphate

C.D.E.P. Mario Ernesto García Briseño

The use of safety graft materials, with predictability and availability, is indicated in intraosseous defect treatment and in tooth extractions where the healing of the alveolar ridge is compromised. A clinical case is presented with both conditions and the osseous graft substitute, R.T.R., is used in their treatment.

Introduction

The inflammatory response as a result of periodontal infection leads to the loss of tooth support tissues¹. The alveolar bone and its three components, cortical plates, trabecular bone and bundle bone (alveolar bone proper), are lost through periodontal infection². Other conditions can worsen the periodontal condition, mainly endodontic, prosthetic and traumatic complications^{3,4,5}. When the tooth extraction is indicated, the anatomic characteristics of the alveolus, the associated lesion and phenotype of the periodontal tissues can lead to a healing of the alveolar ridge with an inadequate morphology

to the replacement of the lost tooth with fixed/removable prosthetics and/or dental implants^{6,7,8}. Restoration of adequate conditions in the periodontium destroyed by periodontal infection to preserve the dentition in health and function^{9,10}, and/or maximizing the healing conditions in the alveolar ridge post extraction for prosthetic restoration^{11,12}, is indicated with the use of graft materials. It provides predictable results, safe use and no availability restrictions. These characteristics are present in the synthetic bone graft substitute R.T.R. (beta tricalcium phosphate)^{13,14,15,16}.

Clinical Cases

62-year-old patient with recurrent periodontal disease without infection control after a previous treatment in February 2007. The main concern is “I do not want to lose my teeth”. The clinical aspect shows high plaque score, signs of inflammation, bleeding on probing, periodontal attachment lost and, radiographically, bone lost, pathologic migration and inadequate occlusal relations (*figs. 1,2*). At the beginning of the retreatment the patient was instructed about the problem with emphasis on infection control by meticulous daily plaque control and oral home care. Once the change in attitude and compromise were noted, the treatment plan was initiated.

Diagnosis

Chronic generalized periodontal disease with advanced periodontal attachment lost.

Treatment plan

Flap debridement and scaling and root planing in superior arch and scaling and root planing alone in lower arch. Prognosis in the anterosuperior segment is reserved.

Procedure description

Anterosuperior segment. Flap debridement and scaling and root planning filling the osseous defects with bone graft substitute, R.T.R, and collagen membrane (*Figs. 3,4*).

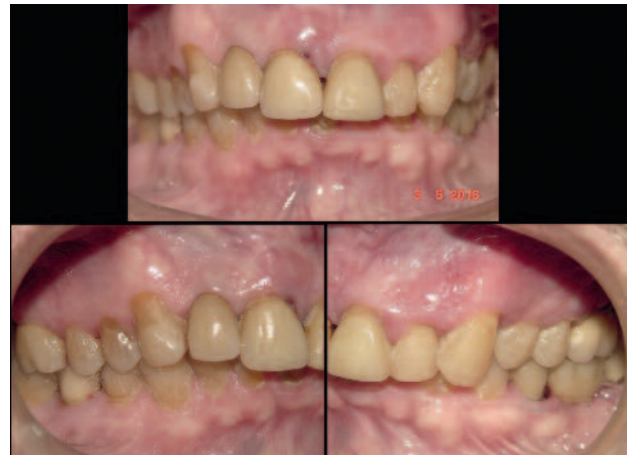

Fig. 1

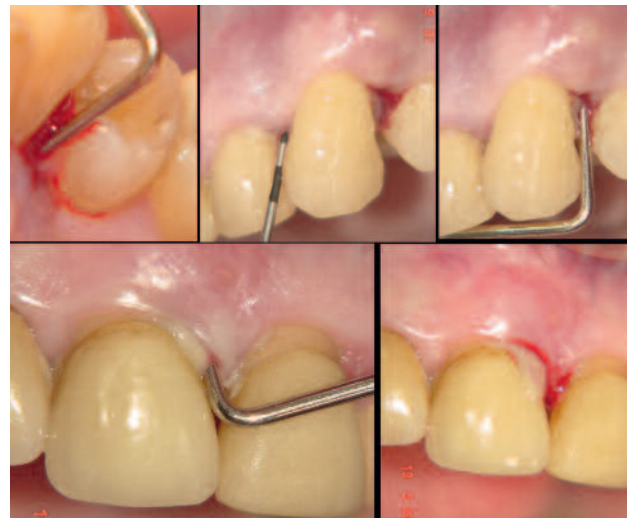

Fig. 2

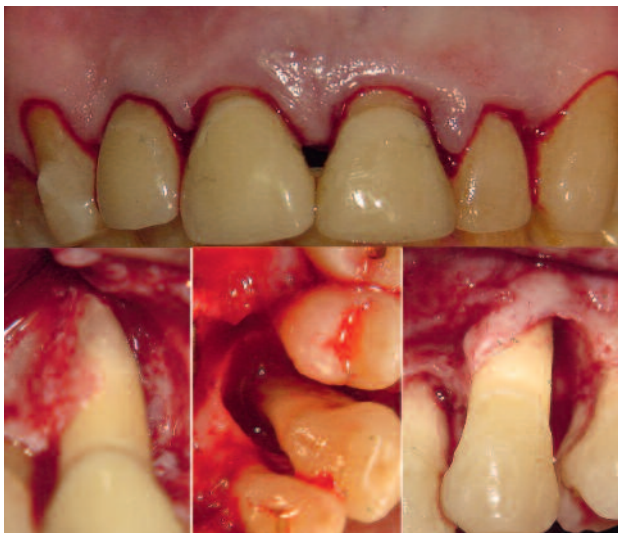


Fig. 3

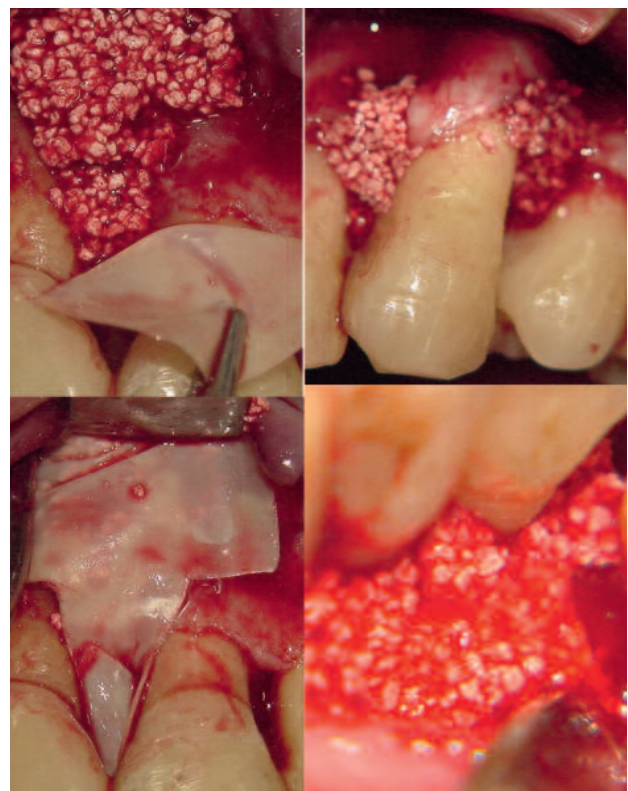


Fig. 4

Healing

The initial radiographs show bone loss and, in radiographs 10 months later, the bone-fill in the defects is evident (*Fig. 5*). Initial clinical view and healing (*Fig. 6*).

In the lower right quadrant, extraction of tooth 46 is depicted. The distal alveolus and bone defect with loss of the vestibular plate was

filled with bone graft substitute, R.T.R. cones. The blood clot covers the intact alveolus of the mesial root (*Fig. 7*).

Figure 9 shows the complete osseous filling of the osseous defect and the compromised socket post extraction at the time of the implant surgery with bone regeneration at 9 months, and radiographic evidence.

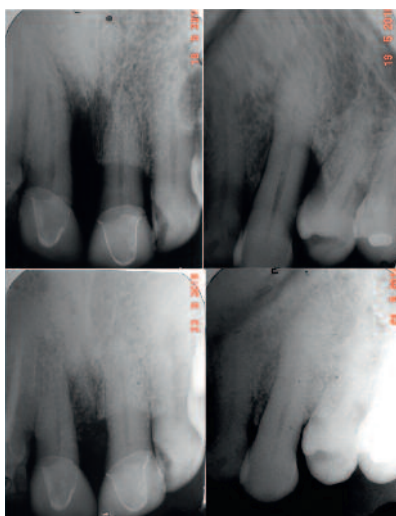


Fig. 5

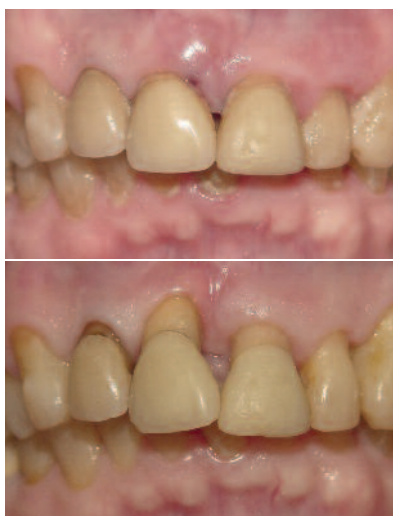

Fig. 6

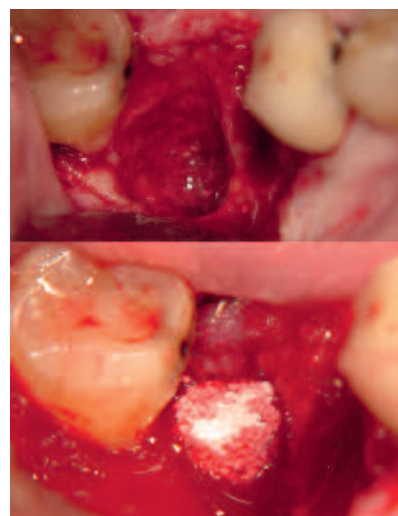


Fig. 7

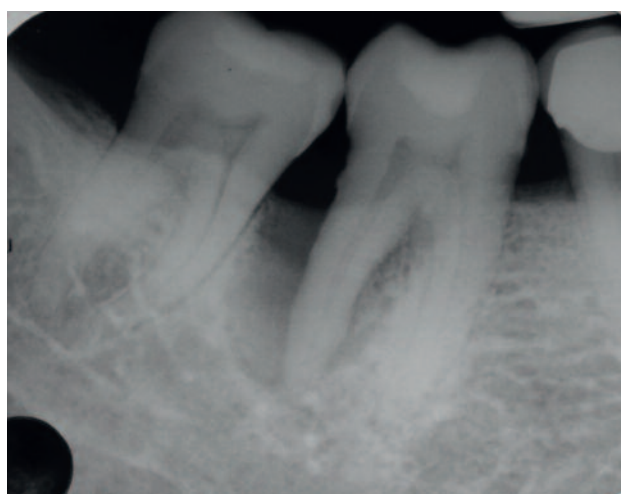

Fig. 8: View of the radiographic initial lesion.

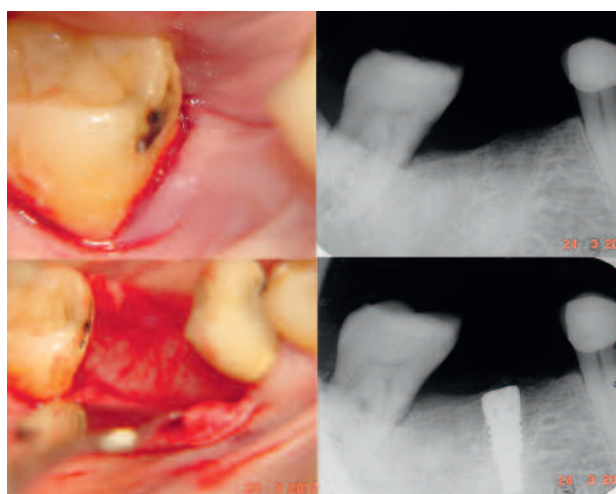


Fig. 9

Conclusion

Loss of periodontal attachment and the consequent alveolar bone destruction resulting from the periodontal infection require procedures to provide periodontal regeneration. This goal requires an accurate diagnosis of the condition and high practitioner skills. Predictability is restricted to certain situations. The loss of the bone morphology in the residual ridge post extraction is worse if combined with periodontal attachment loss, extraction procedure compli-

cations, periapical lesions and/or traumatic events. Prevention and improvement of the healing post extraction is a common procedure with restorative, prosthetic and implant dentistry. The use of a bone substitute graft material like beta tricalcium phosphate (R.T.R., Septodont) ensures biologically secure procedures, predictability in results and total availability. The clinical results are adequate and scientific evidence-based.



Authors:

Mario Ernesto García Briseño

Graduated from the Universidad Autónoma of Guadalajara as a Dental Surgeon (1971-1976).

Specialty in Periodontics at the Universidad Nacional Autónoma of México (1985-1987).

Coordinator of the specialty program in Periodontology at the Universidad Autónoma of Guadalajara from 1993 to 2015 (22 years).

Professor of the Pathogenesis of Periodontal Disease I and II, Etiology of Periodontal Disease, Occlusion, IV Periodontics, Clinical Cases I and II Seminar and Interdisciplinary Seminar in the Periodontics Specialty of the Autonomous University of Guadalajara from 1993 to date.

Instructor in the Periodontics specialty clinic from 1993 to date (24 years).

Professor of the Periodontics Course in the Specialties of Endodontics, Oral Rehabilitation and Orthodontics from 1993 to 2015.

Founding Member of the Mexican Association of Periodontology and President Biennium 1996-1998).

Founding Member and Secretary in the first board of directors of the Mexican Council of Periodontics 1996.

Certificate no. 005 of the Mexican Board of Periodontics from 1996 to date.

Founder and Academic Coordinator of Periodontology GDL, A.C. College of Periodontist from 2005 to date.

Prize Jalisco Dentistry 2002.

Opinion leader at Crest Oral B.

Leader of opinion in Septodont Mexico.

International lecturer and author of 3 publications of the company Septodont, France.

Member of the Academy of Osseointegration since 2015.

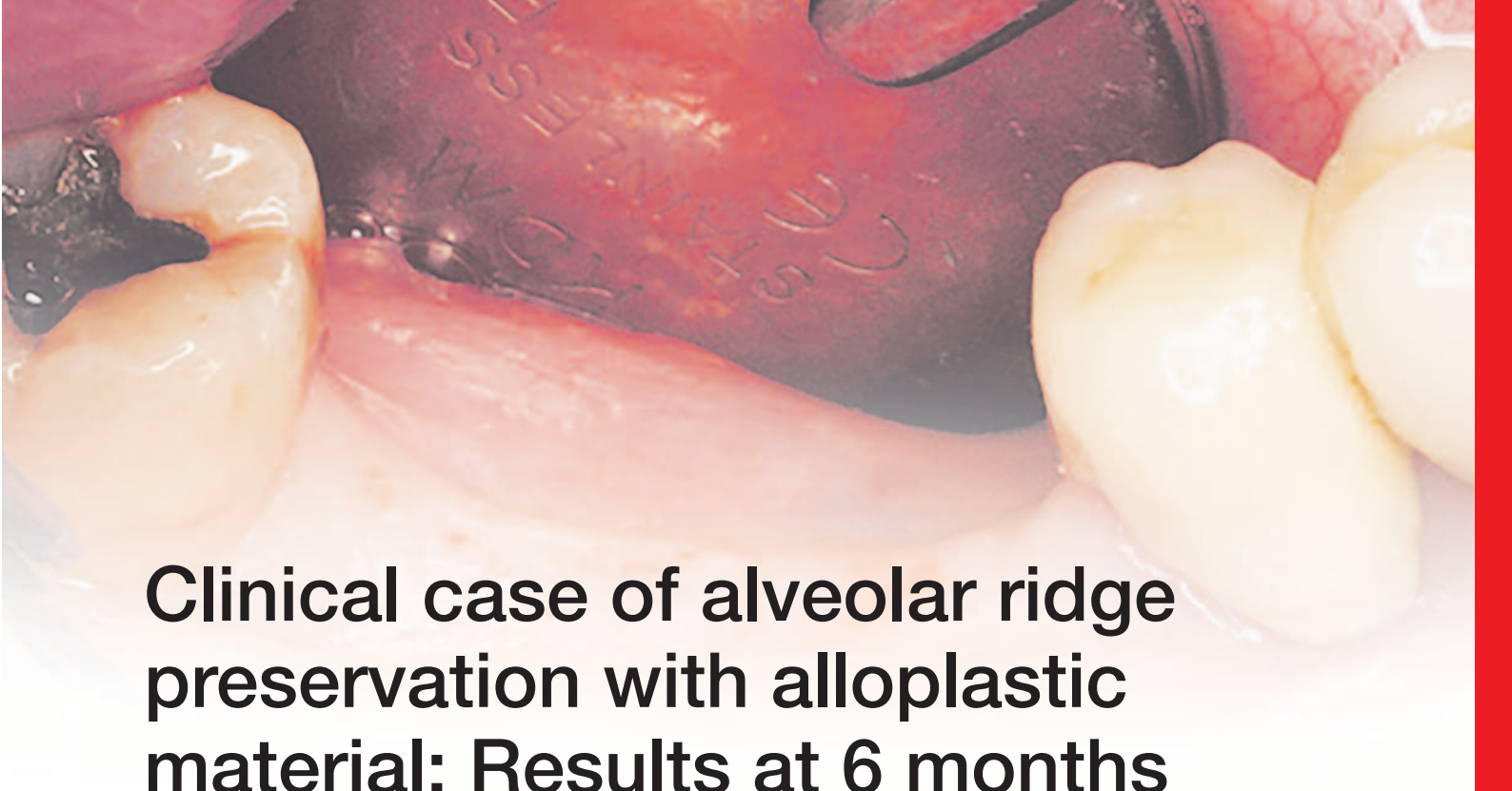
Member of the American Academy of Periodontology 1989 to 2010.

Author of 10 publications in national and foreign journals and 3 international presentations (Webinar) (Coa, Septodont and CMD).

Director and private practice in Professional Periodontology from 1987 to date.

References

01. Listgarten M A: Patogenesis of periodontitis. *J Clin Periodontol* 1986;13:418-425.
02. Waerhaug J. The angular bone defect and its relationship to trauma from occlusion and down growth of subgingival plaque. *J Clin Periodontol*. 1979;6:61-82.
03. Iqbal MK, Kim S. A review of factors influencing treatment planning decisions of single-tooth implants versus preserving natural teeth with nonsurgical endodontic therapy. *J Endod*. 2008;34: 519-529.
04. Zitzmann NU, Krastl G, Walter C et al. Strategic considerations in treatment planning: deciding when to treat, extract, or replace a questionable tooth. *J Prosthet Dent*. 2010;104:80-91.
05. Hiatt WH. Pulpal periodontal disease. *J Periodontol*. 1977;48:598-609.
06. Boyne PJ. Osseous repair of the postextraction alveolus in man. *Oral Surg Oral Med Oral Pathol*. 1966;21:805-813.
07. Pietrokovski J, Massler M. Alveolar ridge resorption following tooth extraction. *J Prosthet Dent*. 1967;17:21-27.
08. Lekovic V, Kenney EB, Weinlaender M et al. A bone regenerative approach to alveolar ridge maintenance following tooth extraction. Report of 10 cases. *J Periodontol*. 1997; 68: 563-570.
09. Bowers GM, Granet M, Stevens M, Emerson J, Coria R, Mellonig J et al. Histologic evaluation of new attachment in humans. *J Periodontol*. 1986; 75: 280-293.
10. Hammerle CH. Membranes and bone substitutes in guided bone regeneration. In: Lang NP, Karring T, Lindhe J, eds. *Proceedings of the 3rd European workshop on periodontology. Implant dentistry*. Berlin: Quintessenz Verlag; 1999. pp.468-499.
11. Avila-Ortiz G, Elangovan S, Kramer KWO, D. Blanchette, Dawson DV. Effect of Alveolar Ridge Preservation after Tooth Extraction: A Systematic Review and Meta-analysis. *J Dent Res*. 2014 93:950-958.
12. Orgeas GV, Clementini M, De Risi V, de Sanctis M. Surgical Techniques for Alveolar Socket Preservation: A Systematic Review *Int J Oral Maxillofac*. 2013;28:1049-1061.
13. Labanca M, Leonida A, Rodella FL. Natural or synthetic biomaterials in dentistry: science and ethic as criteria for their use. *Implantologia*. 2008; 1: 9-23.
14. Metsger DS et al. Tricalcium phosphate ceramic. a resorbable bone implant: review and current status. *J Am Dent Assoc*. 1982; 105: 1035-1038.
15. Jensen SS, Broggini N, Hjorting-Hansen E, Schenk R, Buser D. Bone healing and graft resorption of autograft, anorganic bovine bone and beta-tricalcium phosphate. A histologic and histomorphometric study in the mandibles of minipigs. *Clin Oral Implants Res*. 2006; 17: 237-243.
16. Artzi Z, Weinreb M, Givol N et al. Biomaterial resorption rate and healing site morphology of inorganic bovine bone and beta-tricalcium phosphate in the canine: a 24-month longitudinal histologic study and morphometric analysis. *Int J Oral Maxillofac Implants*. 2004; 19: 357-368.



Clinical case of alveolar ridge preservation with alloplastic material: Results at 6 months

Selene P. Navarro Suárez. Odontologist. Master in dental surgery, Seville.

Daniel Torres Lagares. Co-director, Master in dental surgery course, Seville.

Jose Luis Gutiérrez Pérez. Co-director, Master in dental surgery course, Seville.

Introduction

The aim of this study is to demonstrate the results of treatment with dental implants placed after using bone filling biomaterial: beta-tricalcium phosphate (RTR bone grafting material - Septodont). As is known, when the absence of a tooth is to be restored through a dental implant after extraction, even though the implant is not placed immediately for a reason, e.g. infection in the dental alveolus, the alveolus is preserved to minimize bone resorption as far as possible. The postextraction resorption or bone loss mainly occurs in the vestibular wall. The measurements were made at 1.24 mm (vertical) and 3.79 mm (horizontal).¹ Some authors estimate that 50% of the resorption volume occurs in the 12 months following the extraction and that two-thirds of this volume are lost in the first three months.² The need to maintain hard and soft tissue means that it is crucial to avoid or minimize the bone resorption caused by the loss of a tooth.

Current studies indicate that, using the socket preservation technique, it is possible to reduce this loss of volume by around 1 mm vertically and around 3 mm horizontally.³ In the case shown here, the patient presented an infected alveolus due to failed endodontic treatment and irreparable fracture. Given the risk involved in placing an implant in these conditions, it was decided to carry out the procedure in a second session. In these cases, the preservation of the alveolus is highly recommended to avoid bone resorption as far as possible. From among the techniques available, we opted for filling with biomaterial of choice. The different steps taken are documented in a previous article. Once the regeneration period was over, we took a 3D image of the dental arch to plan the placement of the implant, which we describe below.

Clinical Case

The implants were placed six to nine months after the regenerative surgery following a surgical protocol similar to the one previously indicated for the extraction. The 53-year-old female patient was anaesthetized in the area, a crestal incision made (Fig. 1-4) with mucoperiosteal flap [total thickness] procedure without any vertical incisions. We visualised the appearance of the regenerated bone (Fig. 5) in line with the 3D image (Fig. 1-3) previously made and studied. We placed the two implants (Figs. 6-8) in accordance with the manufacturer's milling protocol (Straumann®). Finally, the flap was adapted by suturing and a post-operative image was taken (Fig. 9-10). The patient was advised to rinse with 0.5 chlorhexidine three times a day for 10 days, starting from the second day. As medical treatment, 1 g of amoxicilin every 8 hours for 7 days and 600 mg of Ibuprofen every 8 hours for days. The stitches were removed after 10 days. The patient was checked over three months, and the re-entry and placement of the healing abutments carried out to create the soft tissue and begin the prosthetic procedure.

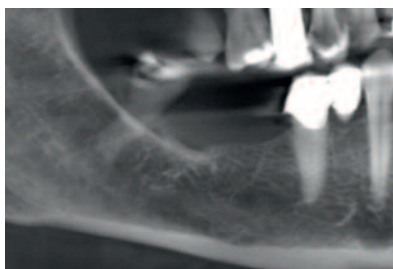


Fig. 1: Control Preoperative radiography of alveolar preservation.

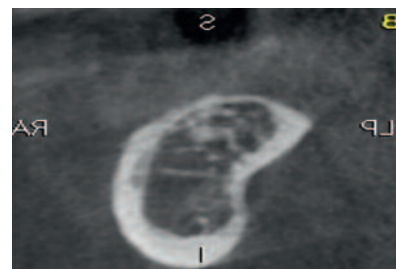

Fig. 2: 3D study cut.

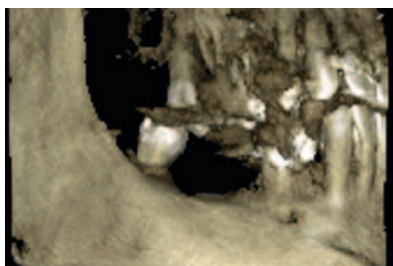


Fig. 3: 3D reconstruction where the height of the preserved ridge is seen.

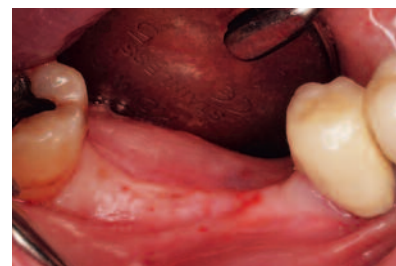

Fig. 4: Preoperative intraoral view of the quadrant to be intervened.

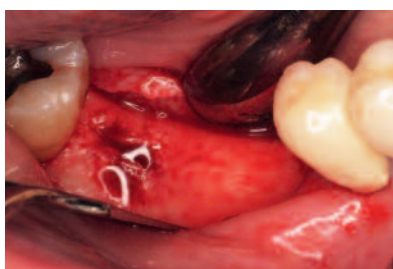

Fig. 5: Image showing the height and width of the preserved alveolar ridge.

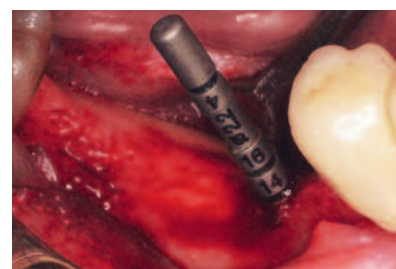

Fig. 6: Image of implant placement process I.

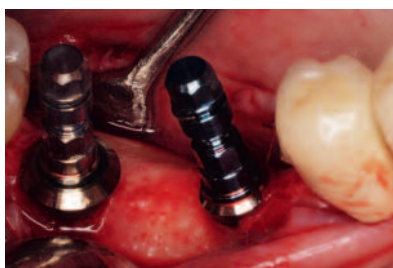


Fig. 7: Image of implant placement process II.

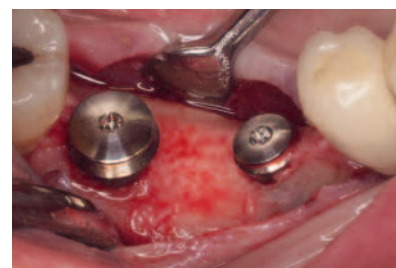


Fig. 8: Placement of the two implants in an ideal position.

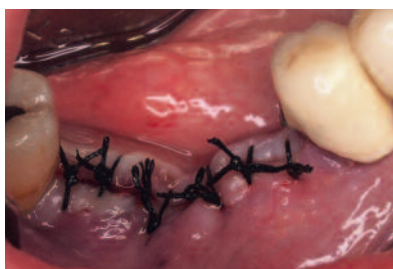

Fig. 9: Immediate postoperative image where the suture is observed.

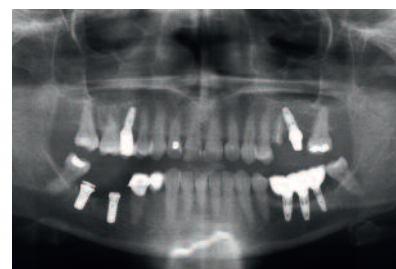

Fig. 10: Immediate postoperative orthopantomography radiography.

Discussion

The dimensional changes in the alveolar ridge following a tooth extraction considerably compromise the functional and aesthetic results of restorations made in partially edentulous areas.

The restoration of isolated alveolar defects using implants, as is the case here, shows that bone regeneration through the use of beta-

tricalcium phosphate is an option to be considered, both from the clinical point of view and from the patient's perspective.

Following a healing period of between 6-9 months it was possible to place the implants without the need for any other regeneration procedure.⁴⁻⁷

Conclusion

The case presented indicates that beta-tricalcium phosphate (RTR bone grafting material - Septodont) can be used successfully for bone regeneration in dental implant treatment.

One of the main advantages of this technique is the elimination of the inevitable morbidity and problems associated with autologous bone

graft, both in the intraoral and the extraoral areas.⁸⁻¹¹

The patient's opinion on the treatment was very positive, both on the process itself and on the appearance achieved, and on the functioning observed after 12 months of monitoring.



Authors:

Selene P. Navarro Suárez

Dentist, University of Seville.

Master Oral Surgery, University of Seville.

Assistant Professor of the Master of Oral Surgery, University of Seville.

Member of the Spanish Society of Oral Surgery (SECIB)

Private practice limited to oral surgery.

Daniel Torres Lagares

Co-director, Master in dental surgery course, Seville.

Jose Luis Gutiérrez Pérez

Co-director, Master in dental surgery course, Seville.

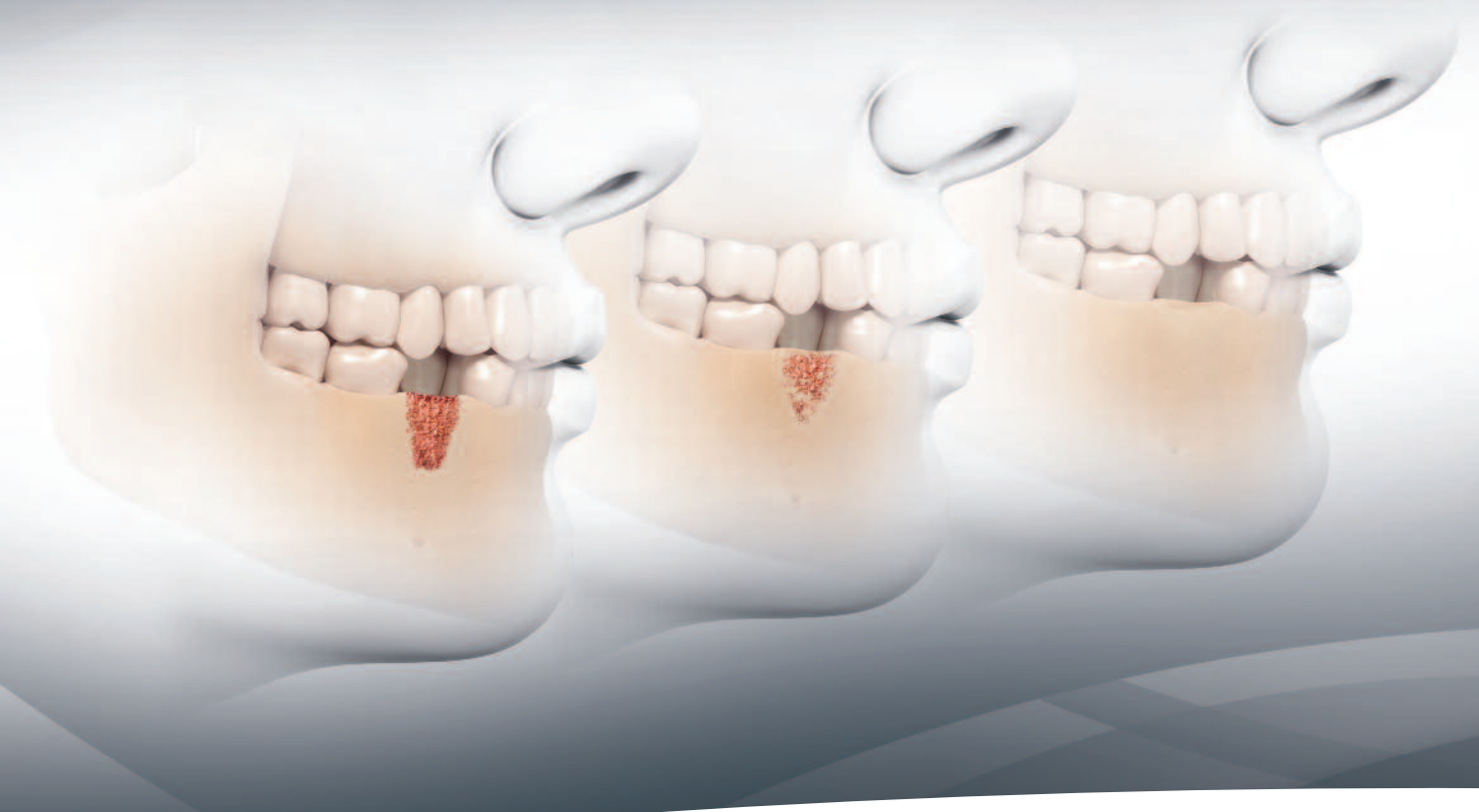References

01. Tan WL, Wong TL, Wong MC, Lang NP. A systematic review of post-extraction alveolar hard and soft tissue dimensional changes in humans. *Clin Oral Implants Res.* 2012 Feb;23 Suppl 5:1-21
02. Schropp L, Wenzel A, Kostopoulos L, Karring T. Bone healing and soft tissue contour changes following single-tooth extraction: a clinical and radiographic 12-month prospective study. *Int J Periodontics Restorative Dent.* 2003 Aug;23(4):313-23.
03. Orgeas et al. Surgical Techniques for Alveolar Socket Preservation: A systematic Review. *Int. J. Oral Maxillofac. Implants.* 2013; 28: 1049-1061.
04. Nkenke E, Schulze-Mosgau S, Radespiel M. Morbidity of harvesting of chin grafts: A prospective study. 2001. *Clin Oral Implants Res* 12:495-502.
05. Silva FM, Cortez AL, Moreira RW, Mazzonetto R. Complications of intraoral donor site for bone grafting prior to implant placement. *Implant Dentistry* 2006. 15, 420-426
06. Nkenke E, Wcisbach V, Winckler E, Kessler P. Morbidity of harvesting of bone grafts for the iliac crest for preprosthetic procedures: A prospective study. *Int J Oral Maxillofac Surg.* 2004. 33:157-163.
07. Bagain ZH, Anabtawi M, Karaky AA, Malkawi Z. Morbidity from anterior iliac crest bone harvesting for secondary alveolar ridge augmentation: an outcome assessment study. *Journal of Oral & Maxillofacial Surgery.* 2009. 67, 570- 575.
08. Antoun H, Sitbon JM, Martinez H, Missika P. A prospective randomized study comparing two techniques of bone augmentation: inlay graft alone or associated with membrane. *Clinical Oral Implants Research.* 2001. 12, 632-639.
09. Friedmann A, Strietzel FP, Maretzki B, Pitaru S, Bernimoulin JP. Histological assessment of augmented jaw bone utilizing a new collagen membrane compared to standard barrier membrane to protect a granular bone substitute material. *Clinical Oral Implants Research* 2002. 13, 587-594.
10. Valentini P, Abensur DJ. Maxillary sinus grafting with an organic bovine bone: a clinical report of long-term results. *Int J Oral Maxillofac Implants.* 2003;18:556-60.
11. Wallace SS, Froum SJ, Cho SC, Elian N, Monteiro D, Kim BS, Tarnow DP. Sinus augmentation utilizing anorganic bovine bone (Bio-oss) with absorbable and nonabsorbable membranes placed over the lateral window: histomorphometric and clinical analysis. *International Journal of Periodontics and Restorative Dentistry.* 2005. 25, 844-852.


R.T.R.

Full resorption...

...Strong new bone formation



Cone



Syringe



Granules

R.T.R. (Resorbable Tissue Replacement) is a highly pure β -tricalcium phosphate bone grafting material that helps to safely create new bone formation following an extraction or any bone loss (intra-bony defect, sinus-lift...).

- **Resorbs progressively and fully:** R.T.R. releases calcium and phosphate ions helping to promote strong new bone formation.
- **Regenerates natural bone growth.** Osteoconductive micro and macroporous structures foster dense new bone growth.
- **Restores volume:** R.T.R. renews the bone integrity within 3-6 months.
- **Available in 3 presentations** (Cone, Syringe, Granules) to suit all clinical situations.

Improve your patients' extraction therapy and bone loss repair to promote future implant success with R.T.R.

R.T.R. Cone contains collagen from bovine origin





The Dental Pharmaceutical Company

INNOVATIVE, SAFE AND EFFECTIVE SOLUTIONS FOR DENTISTRY WORLDWIDE